EP trudne przypadki

Maria Miszczak-Knecht

Klinika Kardiologii Instytut „Pomnik-Centrum Zdrowia Dziecka”

Epicardial ablation

Maria Miszczak-Knecht

Klinika Kardiologii Instytut „Pomnik-Centrum Zdrowia Dziecka”

K.O. 7lat

Born at 35 week of gestation

Since 32 week of gestation SVT was recognize

After delivery

- FAT tachycardia was recognized
- Treatment: Amiodaron+ Metoprolol
- ECHO: ASD II, non-compaction LV
- CMV infection – Gancyklovir treatment

K.O. 7lat

Urodzona 35 Hbd cc z ciąży bliźniaczej 4pkt Apg

Wskazanie do cc tachykardia płodu

Badanie USG płodu w 32 Hbd- SvEx

Po urodzeniu:

- Czętoskurcz przedsionkowy umiarowiony Amiodaronem+ Metocard
- ECHO: ubytek przegrody międzyprzedsionkowej i międzykomorowej, niescalony mięsień Lewej komory
- W badaniach dodatkowych rozpoznano wrodzone zakażenie CMV –leczone Gancyklowirem

K.O. 7lat

3/12 Amiodaron was stopped due to TSH increase

Propaphenon and Metoprolol started

At age 5 years physical tolerance decreased

Holter monitoring- episodes of tachycardia acceleration up to 230/min

Changed treatment Propahenon, Propranolol and Digoxin

K.O. 7lat

3/12 mż z powodu narastania poziomu TSH- odstawiono Amiodaron

Włączono Polfenon i Metocard uzyskując umiarowienie

Od 5 rż gorsza tolerancja wysiłku

W zapisach EKG met. Holtera- wielokrotne nawroty częstoskurczu z HR do 220/min

Zmiana leczenia: Propafenon, Propranolol, Digoxin

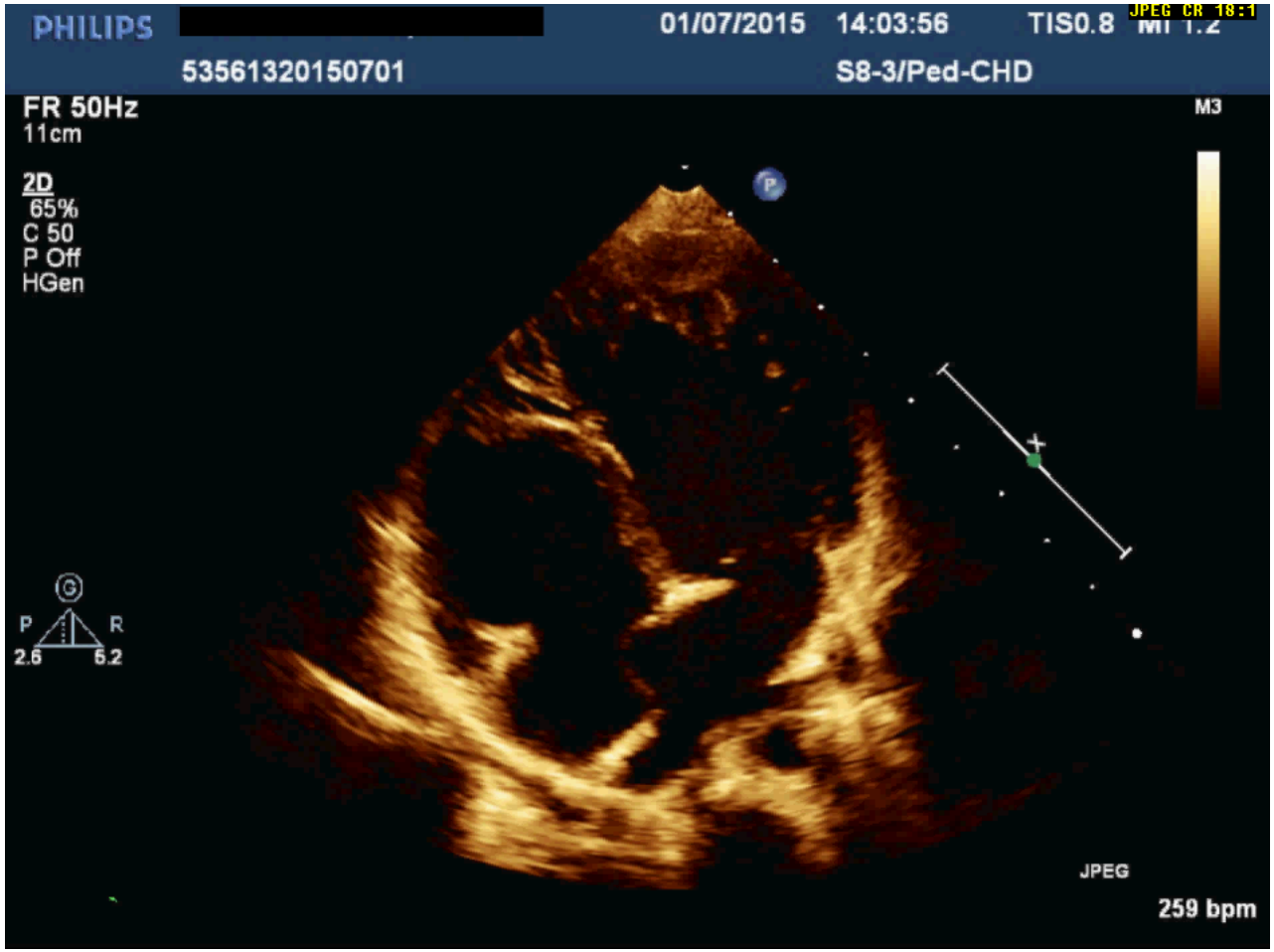
PHILIPS
[redacted]
01/07/2015
14:03:56
TIS0.8
JPEG CR 18:1
53561320150701
S8-3/Ped-CHD
FR 50Hz
11cm
2D
65%
C 50
P Off
HGen
M3
G
P
R
2.6
5.2
JPEG
259 bpm

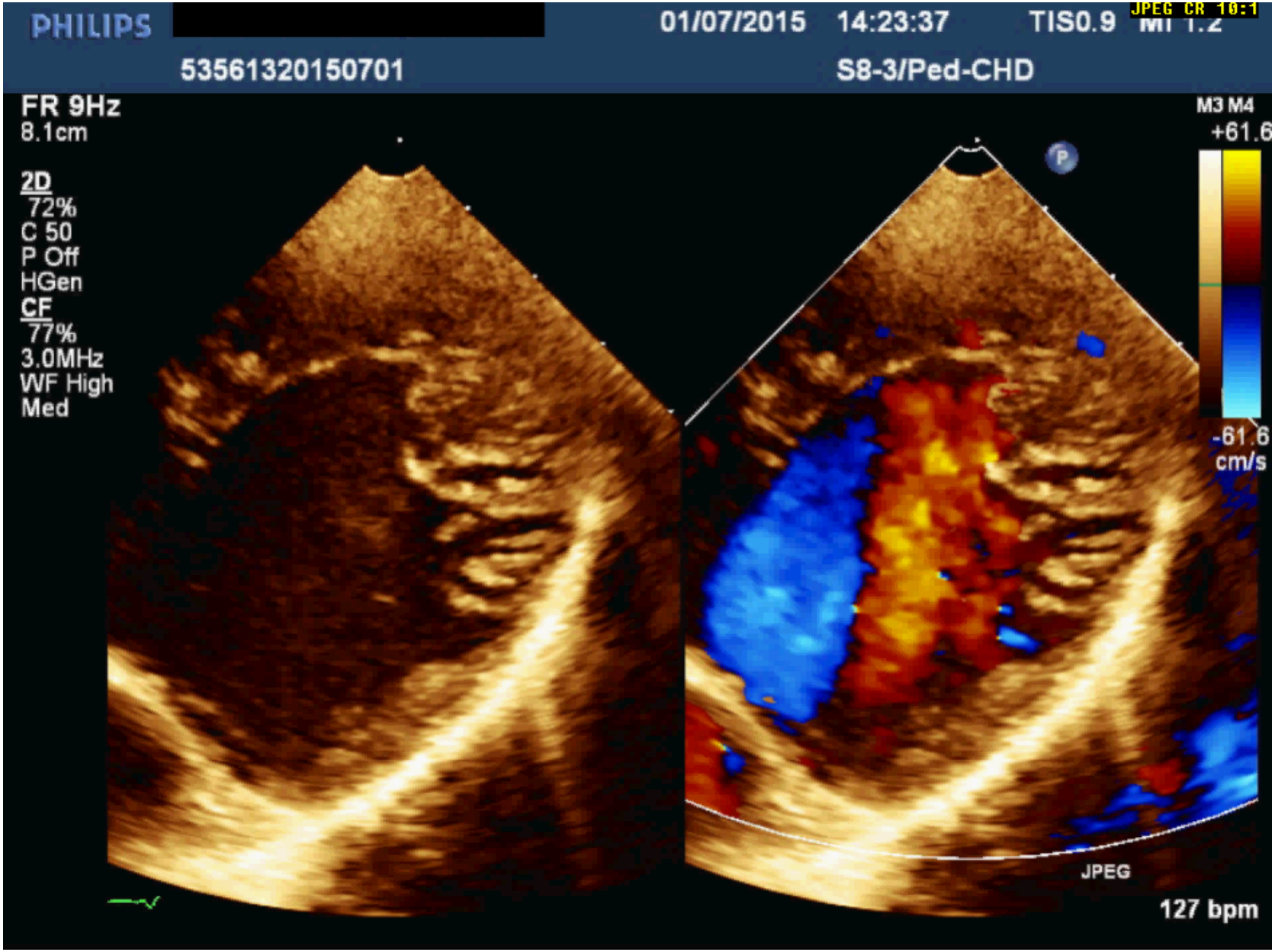
PHILIPS
[redacted]
01/07/2015 14:23:37 TIS0.9 MI 1.2
JPEG CR 10:1
53561320150701
S8-3/Ped-CHD
FR 9Hz
8.1cm
2D
72%
C 50
P Off
HGen
CF
77%
3.0MHz
WF High
Med
M3 M4
+61.6
-61.6
cm/s
JPEG
127 bpm

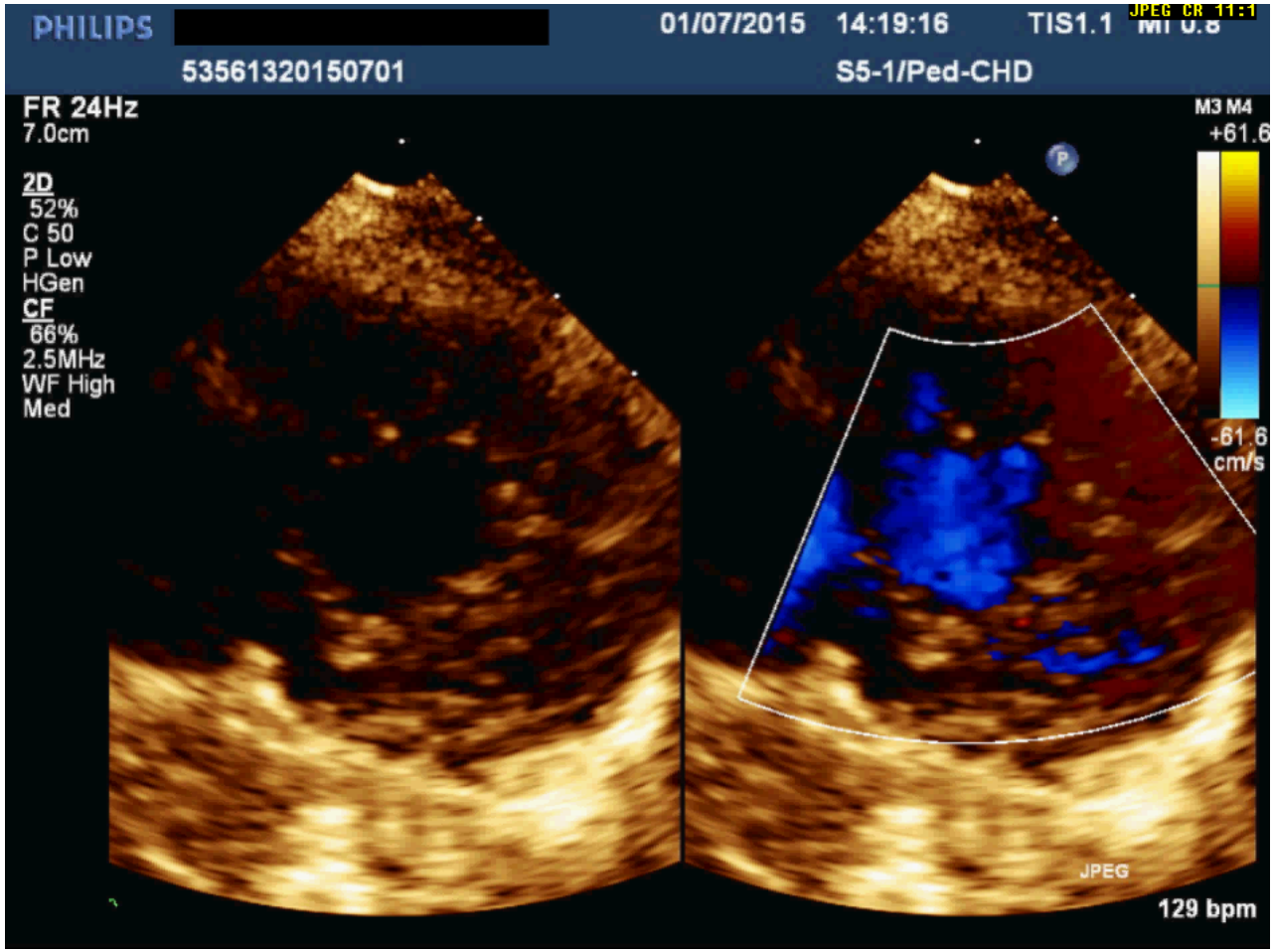
PHILIPS
[redacted]
01/07/2015 14:19:16 TIS1.1
JPEG CR 11:1
53561320150701
S5-1/Ped-CHD
FR 24Hz
7.0cm
2D
52%
C 50
P Low
HGen
CF
66%
2.5MHz
WF High
Med
M3 M4
+61.6
-61.6
cm/s
JPEG
129 bpm

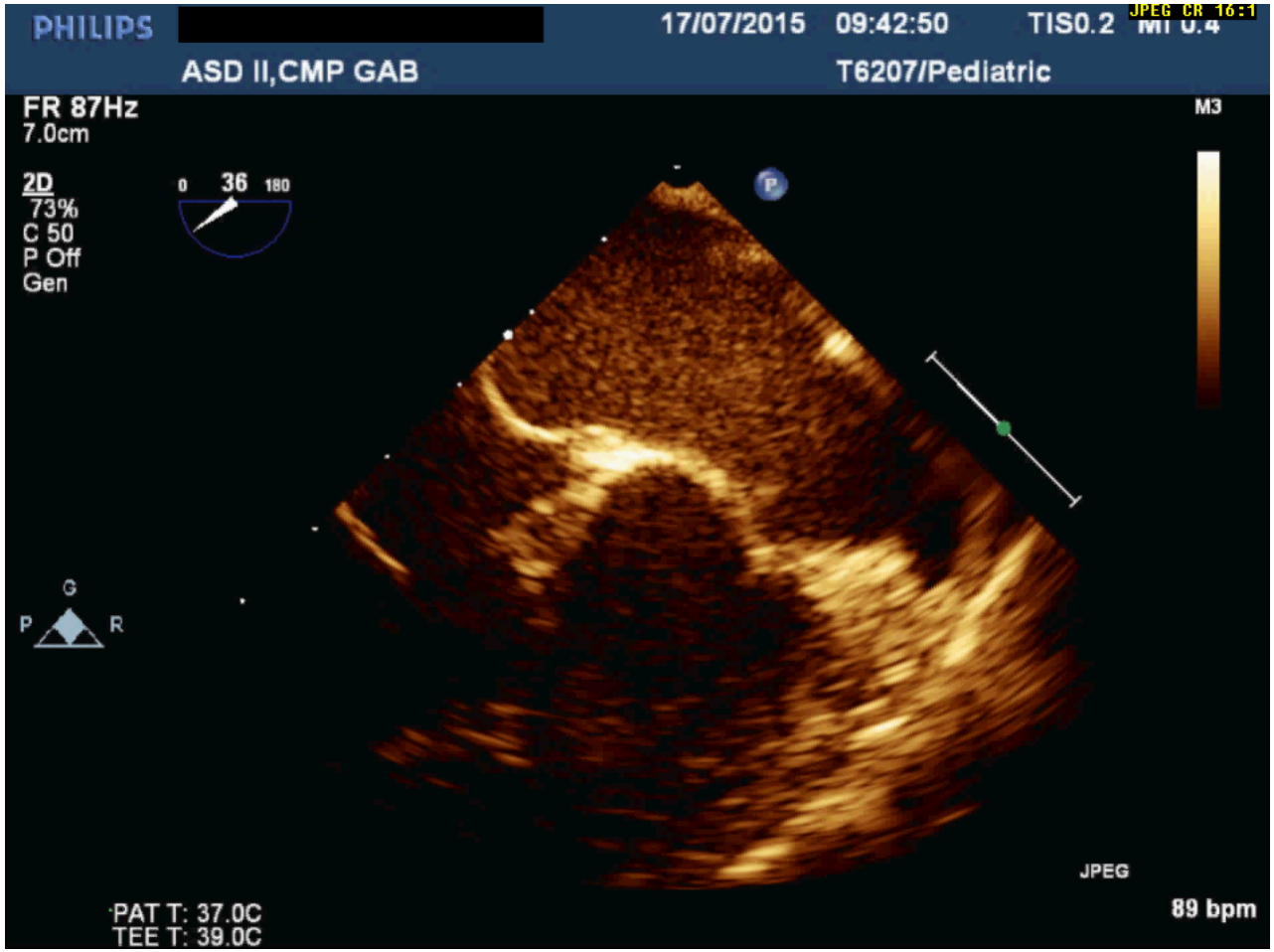
PHILIPS
[redacted]
17/07/2015 09:42:50
TIS0.2
JPEG CR 16:1
ASD II,CMP GAB
T6207/Pediatric
FR 87Hz
7.0cm
2D
73%
C 50
P Off
Gen
0 36 180
M3
G
P R
JPEG
PAT T: 37.0C
TEE T: 39.0C
89 bpm

K.O. 7lat

21.04.2016r – CARTO ablation procedure, localization of AT – left atrial appendage

Few hours after arrhythmia recurrent

30.06.2015 second ablation procedure

K.O. 7lat

Zakwalifikowana do ablacji RF

21.04.2016r – wykonano zabieg ablacji RF metodą CARTO –lokalizacja uszko lewego przedsionka

Bezpośrednio po nawrót arytmii

30.06.2015 kolejna ablacja RF metodą CARTO

ablacja
I
II
III
aVR
UNI
V1
V3
V6
ABL1-2
ABL2-3
ABL3-4
CS 1,2
CS 2,3
CS 3,4
200 ms
11:45:50
11:45:51
11:45:52
CardioLab v5.1D

ablacja

CardioLab v5.1D

After the second procedure:

Better rate control

Episodes of very fast tachycardia (260/min)

?

Po 2-gim zabiegu ablacji kontrola rytmu na 3 lekach antyarytmicznych: Propafenon, Propranolol i Digoxin

Z okresami częstoskurczu do 250/min

?

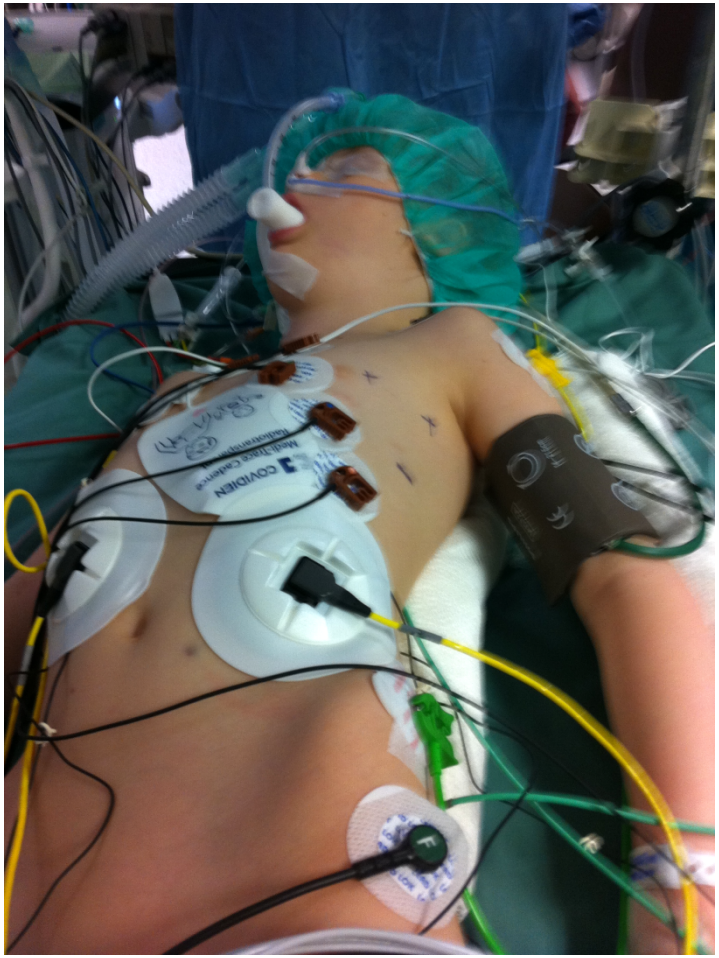
COVIDIEN
Multi-Sites Electrode
Radiotransparent
F

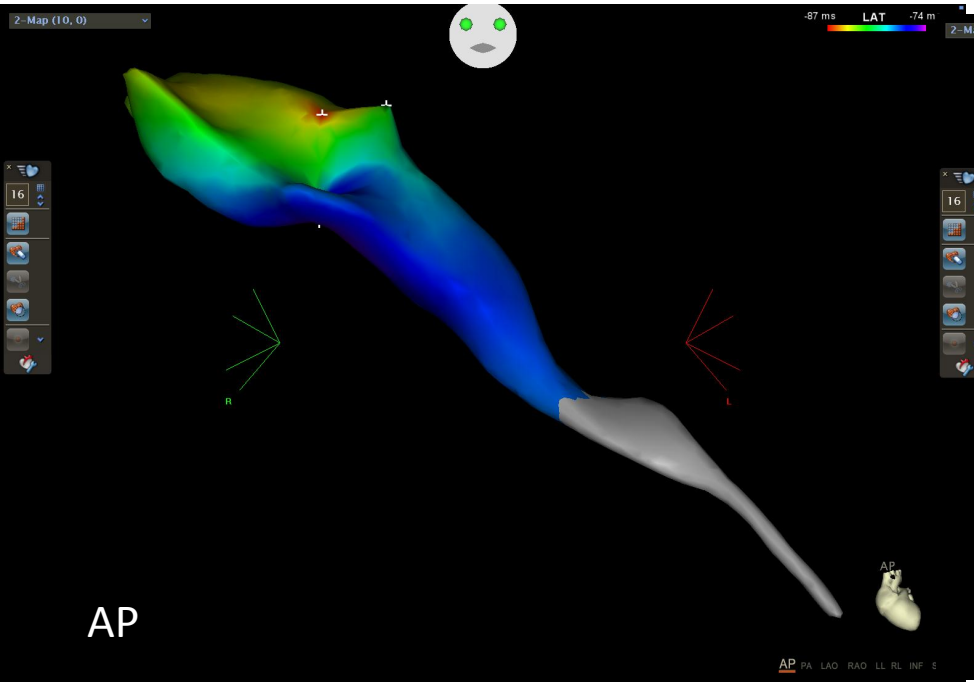

AP

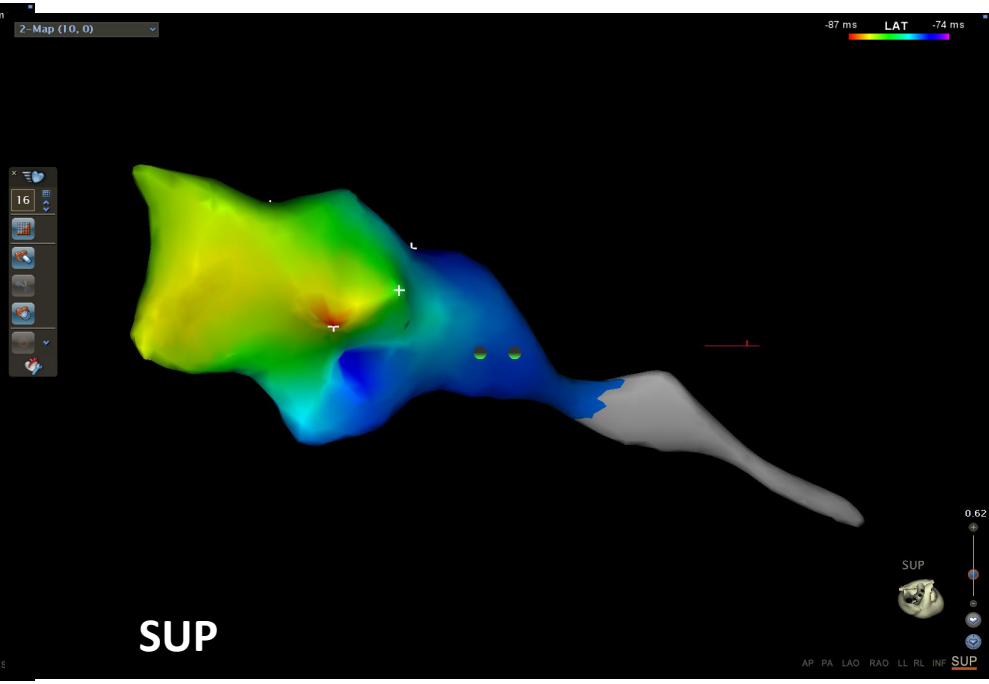

SUP

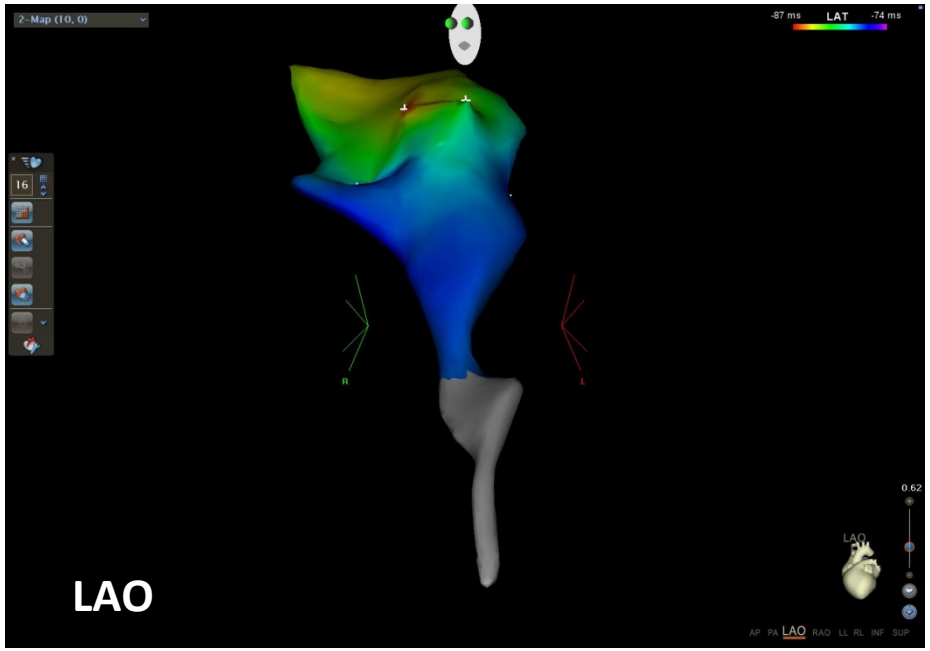

LAO

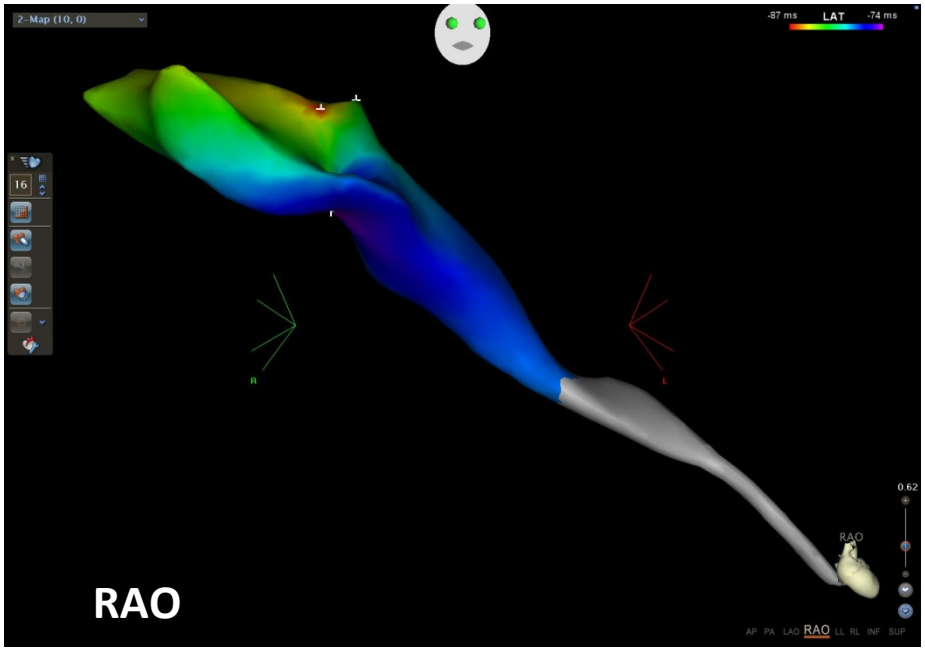

RAO

42.50
43
43.50
44
44.50
I
II
III
aVR
V1
V5
Abl1-2
Abl3-4
Abl uni

K.O. 7lat

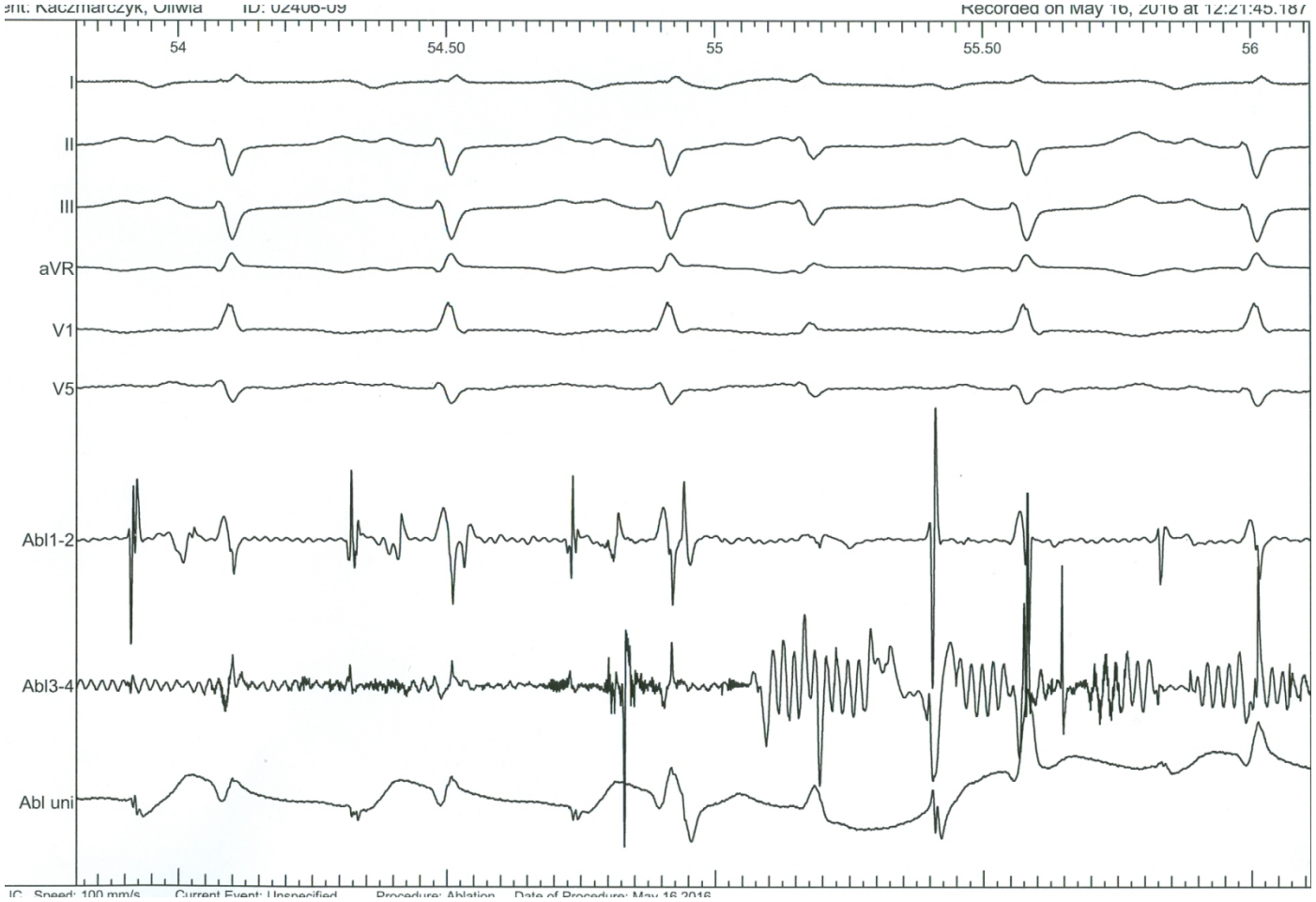

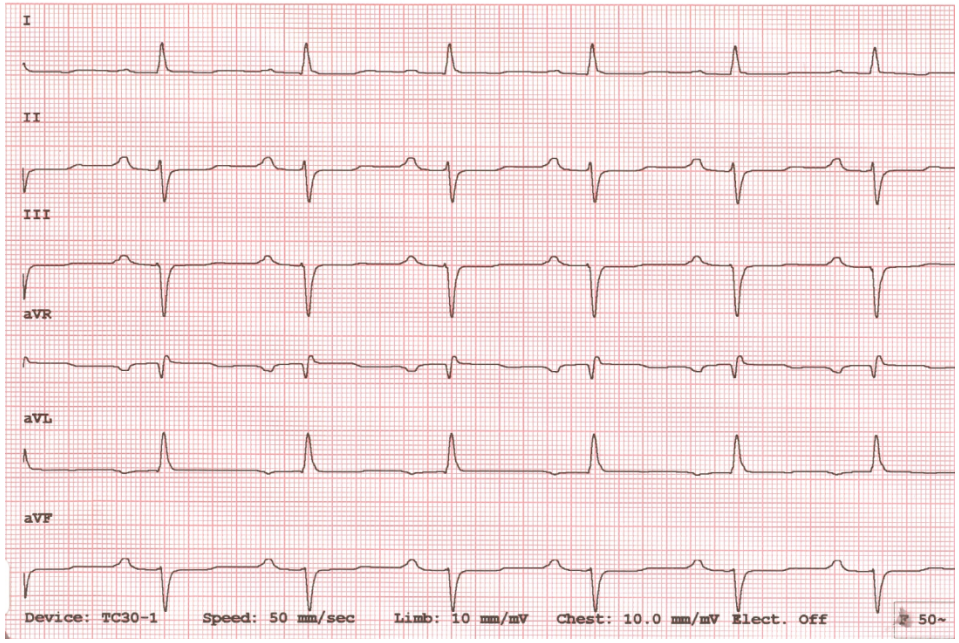
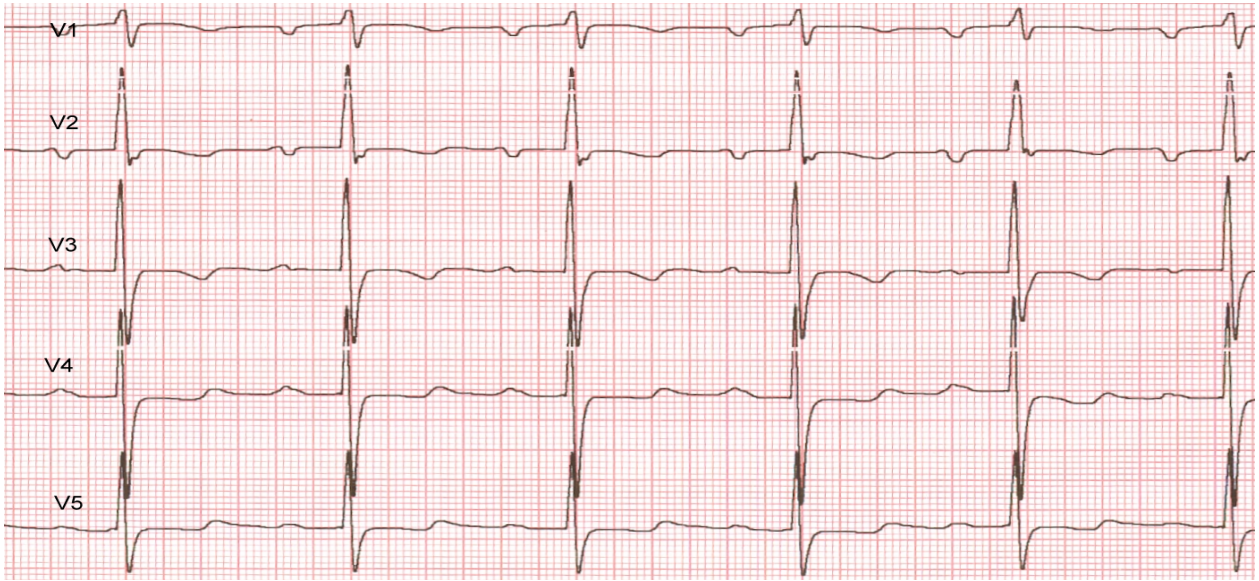
EKG 24 hrs post epicardial ablation