Tips and Tricks for VT ablation: Lessons from Adult Cases II: Stepwise Approach to Ablation

Sedat KÖSE, MD
Department of Cardiology
Liv Hospital
Ankara, TURKEY

CLASSIFICATION OF IDIOPATHIC VT

- Outflow tract VT
  - *RVOT*
  - *LVOT*
  - *Aortic cusps*
- Fascicular VT
  - *Posterior*
  - *Anterior*
  - *Upper septal*
- Annular VT
  - *Mitral*
  - *Tricuspid*
- Papillary muscle VT
- Epicardial VT

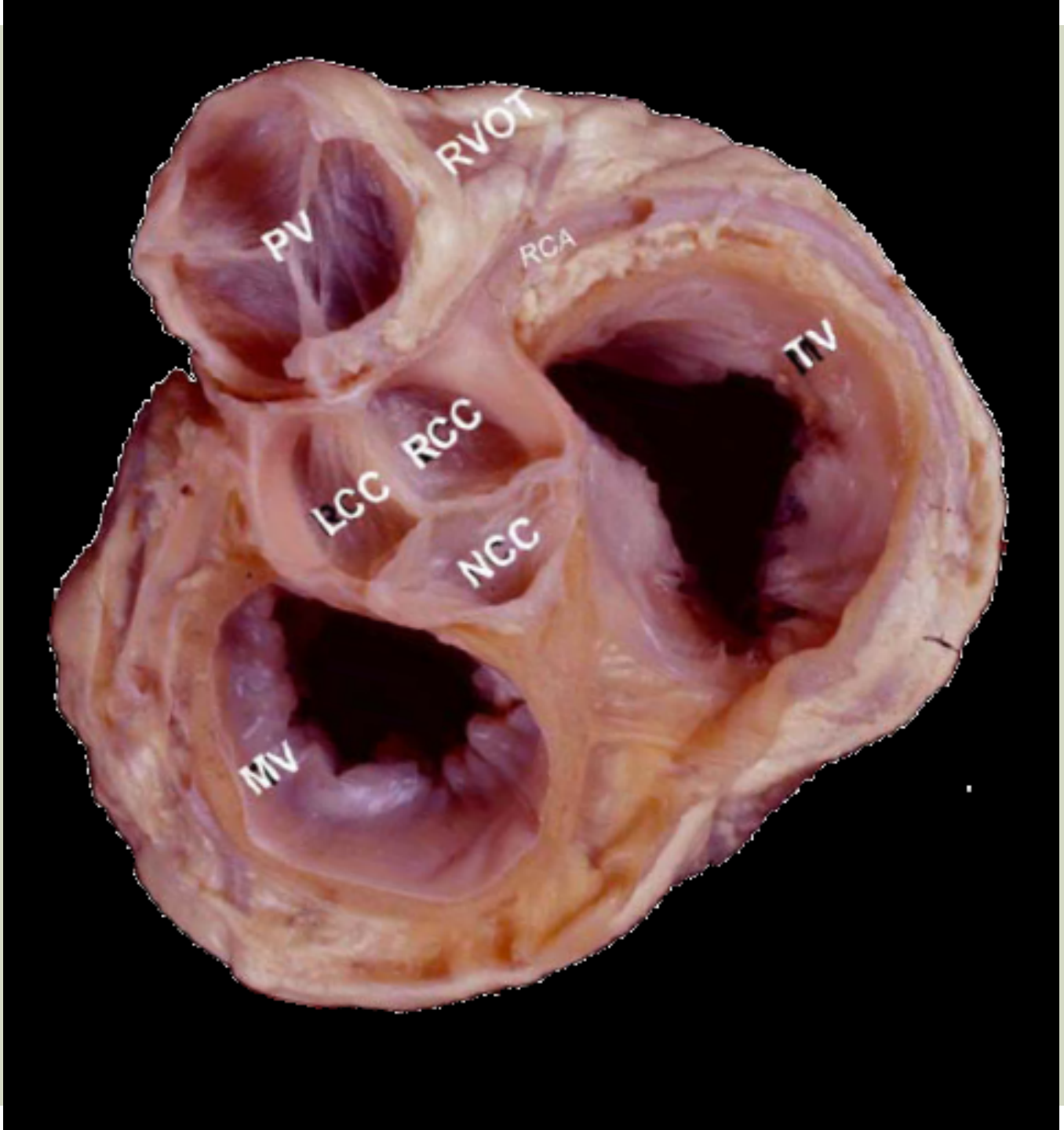
RVOT
PV
RCA
TV
RCC
LCC
NCC
MV

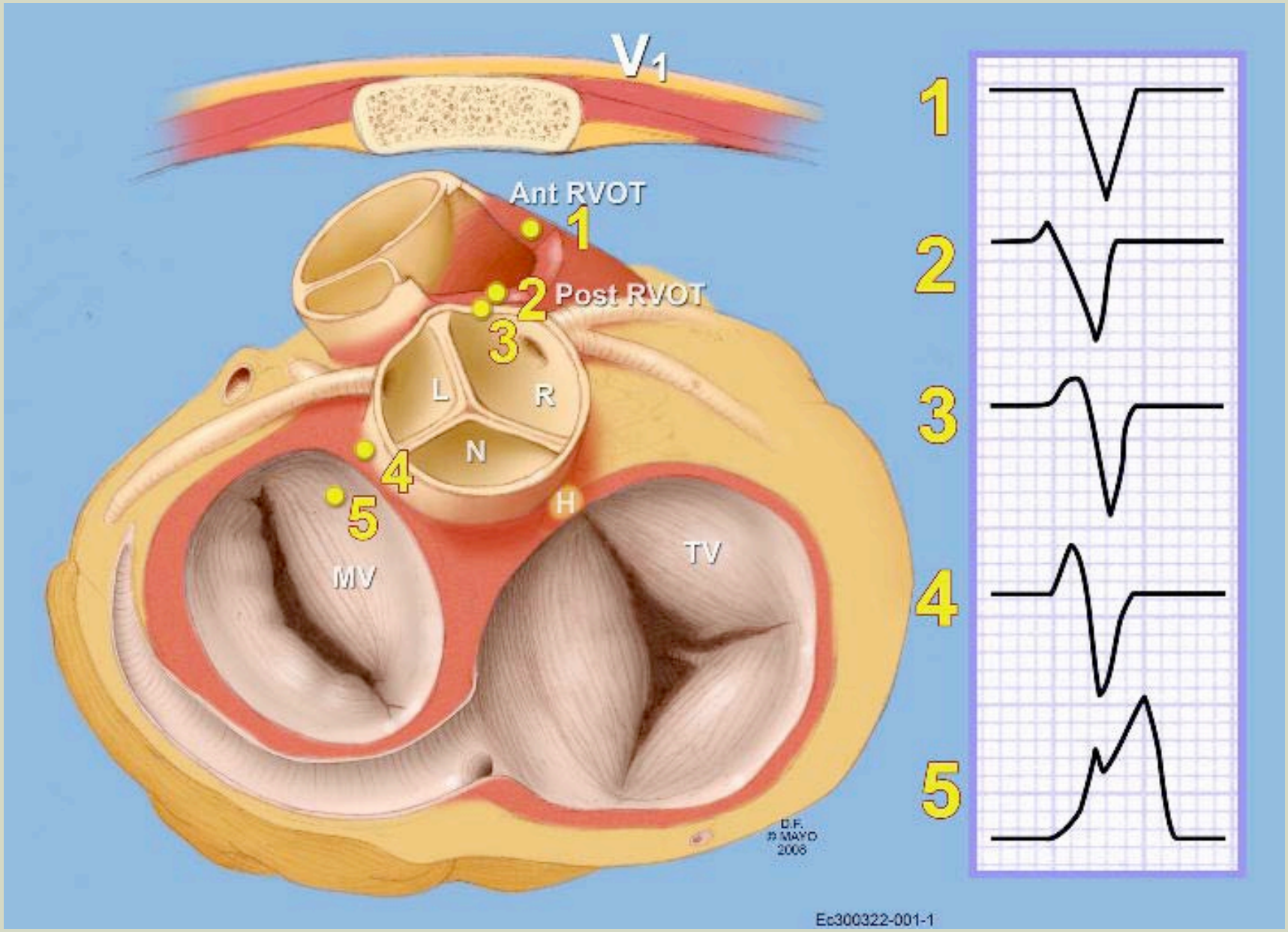

Tabatabaeiand Asirvatham: Circ Arrhyth2010

MANAGEMENT OF VENTRICULAR ARRHYTHMIAS IN CHILDREN WITH A STRUCTURALLY NORMAL HEART

Medical therapy or catheter ablation is recommended in children with frequent PVCs or VT thought to be causative of ventricular dysfunction.	I	C	This panel of experts
Catheter ablation should be considered when medical therapy is either not effective or undesired in symptomatic children with idiopathic RVOT VT/ PVCs or verapamil-sensitive left fascicular VT.	IIa	B	471–474
Catheter ablation by experienced operators should be considered after failure of medical therapy or as an alternative to chronic medical therapy in symptomatic children with idiopathic LVOT, aortic cusps or epicardial VT/ PVCs.	IIa	B	473, 474
Sodium channel blockers (class IC agents) should be considered as an alternative to beta-blockers or verapamil in children with outflow tract VT.	IIa	C	471
Catheter ablation is not recommended in children <5 years of age except when previous medical therapy fails or when VT is not haemodynamically tolerated.	III	B	475

- 2015 ESC Guidelines for the management of patients with ventricular arrhythmias and the prevention of sudden cardiac death, European Heart Journal (2015) 36, 2793–2867 doi: 10.1093/eurheartj/ehv316

TREATMENT OF OUTFLOW TRACT VENTRICULAR TACHYCARDIA

Recommendations	Class[a]	Level[b]	Ref.[c]
Catheter ablation of RVOT VT/PVC is recommended in symptomatic patients and/or in patients with a failure of anti-arrhythmic drug therapy (e.g. beta-blocker) or in patients with a decline in LV function due to RVOT-PVC burden.	I	B	525–528
Treatment with sodium channel blockers (class IC agents) is recommended in LVOT/aortic cusp/epicardial VT/PVC symptomatic patients.	I	C	529–531
Catheter ablation of LVOT/aortic cusp/epicardial VT/PVC by experienced operators after failure of one or more sodium channel blockers (class IC agents) or in patients not wanting long-term anti-arrhythmic drug therapy should be considered in symptomatic patients.	IIa	B	195, 531–533

- 2015 ESC Guidelines for the management of patients with ventricular arrhythmias and the prevention of sudden cardiac death, European Heart Journal (2015) 36, 2793–2867 doi:10.1093/eurheartj/ehv316

TREATMENT TO PREVENT RECURRENCE OF IDIOPATHIC Ventricular Tachycardia

Recommendations	Class[a]	Level[b]	Ref.[c]
Catheter ablation by experienced operators is recommended as a first-line treatment in symptomatic patients with idiopathic left VTs.	I	B	346, 347, 563–575
When catheter ablation is not available or desired, treatment with beta-blockers, verapamil or sodium channel blockers (class IC agents) is recommended in symptomatic patients with idiopathic left VT.	I	C	This panel of expert
Treatment with beta-blockers, verapamil or sodium channel blockers (class IC agents) is recommended in symptomatic patients with papillary muscle tachycardia.	I	C	This panel of experts
Treatment with beta-blockers, verapamil or sodium channel blockers (class IC agents) is recommended in symptomatic patients with mitral and tricuspid annular tachycardia.	I	C	This panel of experts
Catheter ablation under echo guidance by experienced operators after failure of one or more sodium channel blockers (class IC agents) or in patients refusing long-term anti-arrhythmic drug therapy should be considered in symptomatic patients with papillary muscle tachycardia.	IIa	B	576–578
Catheter ablation by experienced operators after failure of one or more sodium channel blockers (class IC agents) or in patients not wanting long-term anti-arrhythmic drug should be considered in symptomatic patients with mitral and tricuspid annular tachycardia.	IIa	B	534, 579–581

- 2015 ESC Guidelines for the management of patients with ventricular arrhythmias and the prevention of sudden cardiac death, European Heart Journal (2015) 36, 2793–2867 doi:10.1093/eurheartj/ehv316

TREATMENT OF IDIOPATHIC VENTRICULAR FIBRILLATION

Recommendations	Class[a]	Level[b]	Ref.[c]
ICD implantation is recommended in survivors of idiopathic VF.	I	B	154, 583
Catheter ablation of PVCs triggering recurrent VF leading to ICD interventions is recommended when performed by experienced operators.	I	B	467, 584–587
Catheter ablation of PVCs leading to electrical storm is recommended when performed by experienced operators.	I	B	467, 584–587

CASE 1

- 35 year old male
- Complaint of palpitation for 2 years
- resistant to antiarrhythmics
- 11000 pvc/24 hours
- No organic heart disease

İŞLEM ÖNCESİ 1. MORFOLOJİ

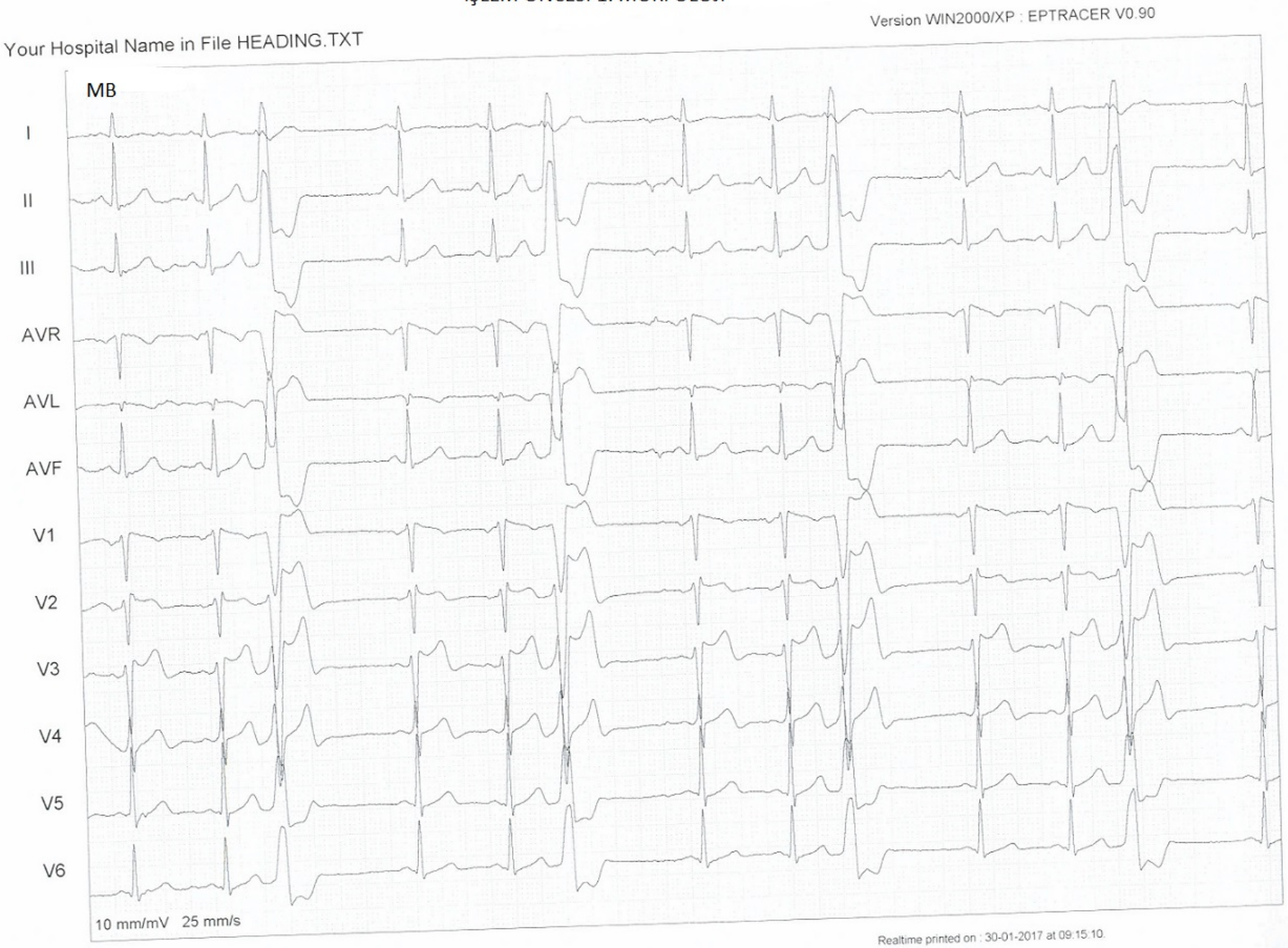

1. morfeloji artmış yer.

Version WIN2000/XP : EPTRACER V0.90

Your Hospital Name in File HEADING.TXT

Patient : bahadir mehmet / ves / File : C:\PAT\mehmet bahadir\RF GGTI.000
Comment :

Offline printed on : 30-01-2017 at 09:59:18.
File recorded on : 30.01.2017 at 09:37:22. Time in file 40180 msec.

2. MORFOLOJİ

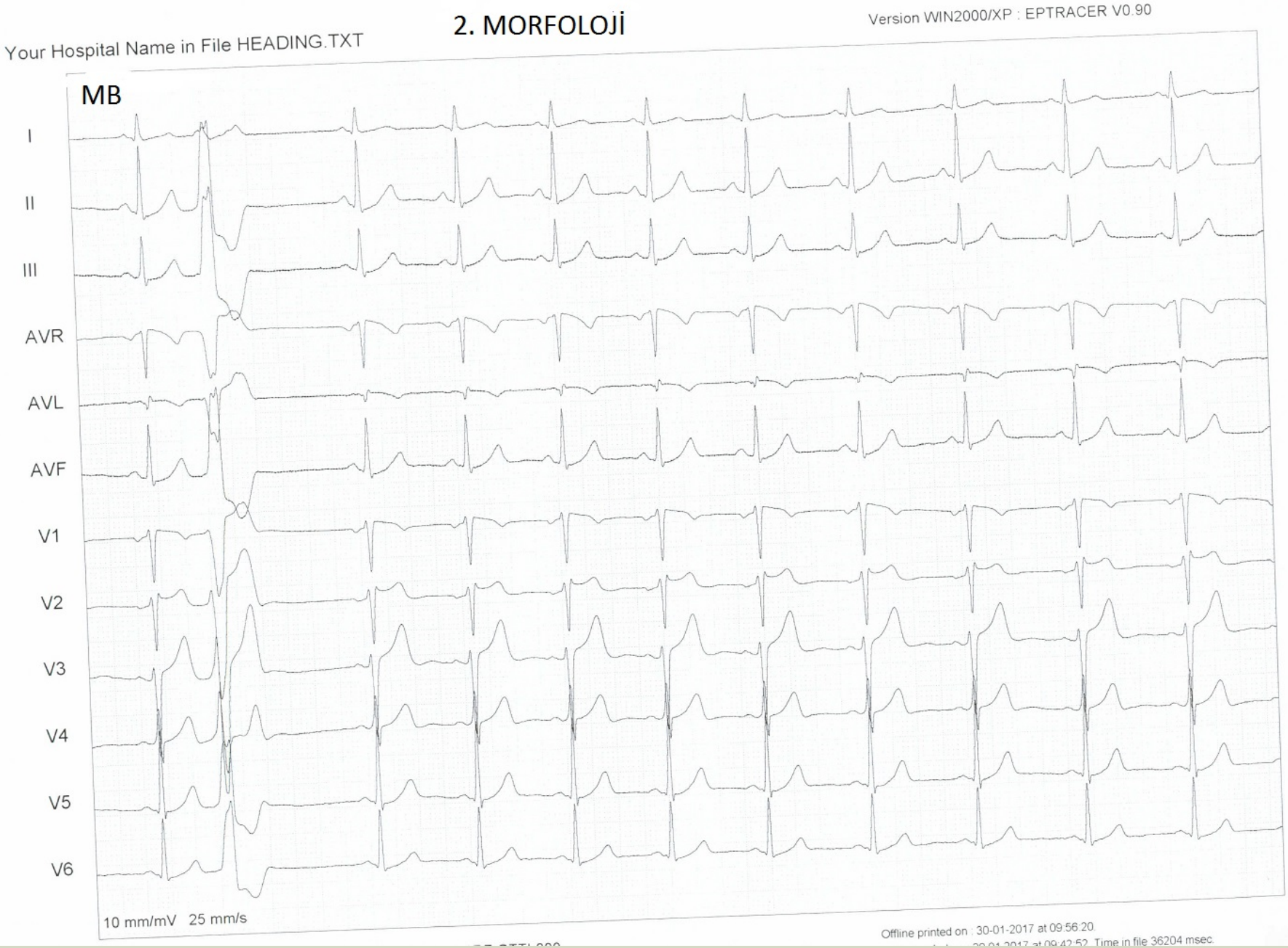
Your Hospital Name in File HEADING.TXT
Version WIN2000/XP : EPTRACER V0.90
MB
I
II
III
AVR
AVL
AVF
V1
V2
V3
V4
V5
V6
10 mm/mV 25 mm/s
Offline printed on : 30-01-2017 at 09:56:20.

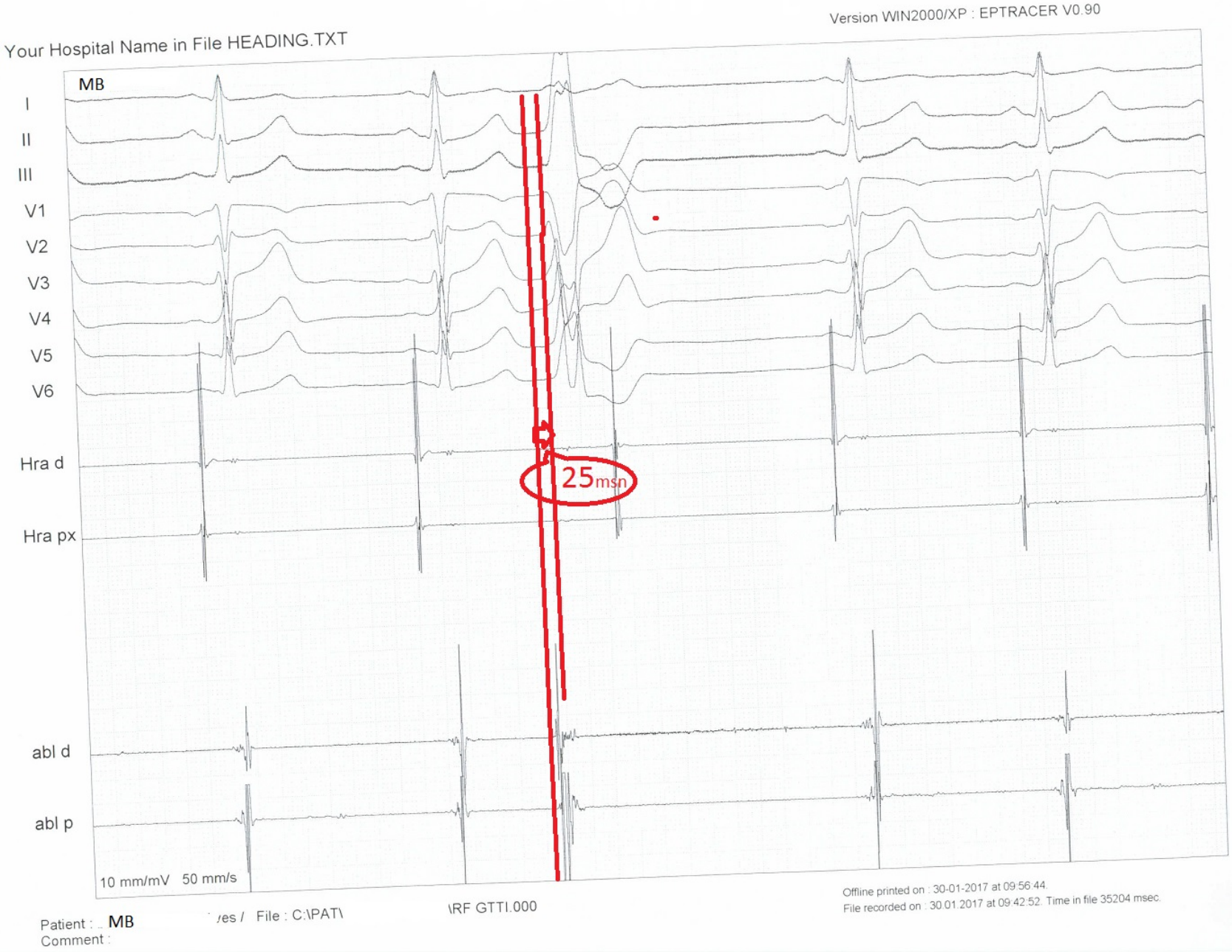
Version WIN2000/XP : EPTRACER V0.90
Your Hospital Name in File HEADING.TXT
MB
I
II
III
V1
V2
V3
V4
V5
V6
Hra d
Hra px
25msn
abl d
abl p
10 mm/mV 50 mm/s
Patient : MB
Comment :
/es / File : C:\PAT\
\RF GTTI.000
Offline printed on : 30-01-2017 at 09:56:44.
File recorded on : 30.01.2017 at 09:42:52. Time in file 35204 msec.

İŞLEM SONRASI

Version WIN2000/XP : EPTRACER V0.90

Your Hospital Name in File HEADING.TXT

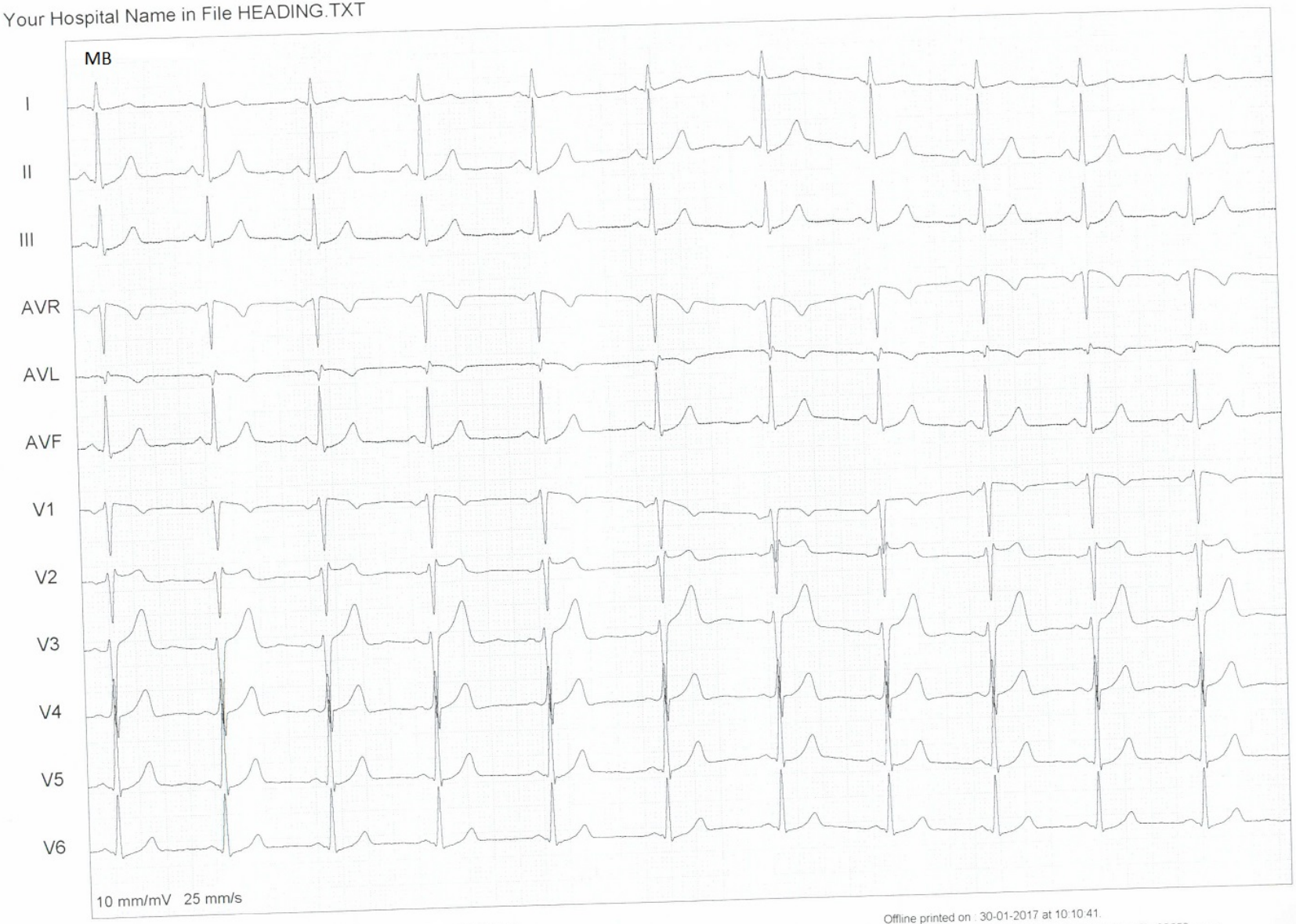

Patient : MB / ves / File : C:\PAT\ \RF.003

Comment :

Offline printed on : 30-01-2017 at 10:10:41.
File recorded on : 30.01.2017 at 09:43:24. Time in file 32652 msec.

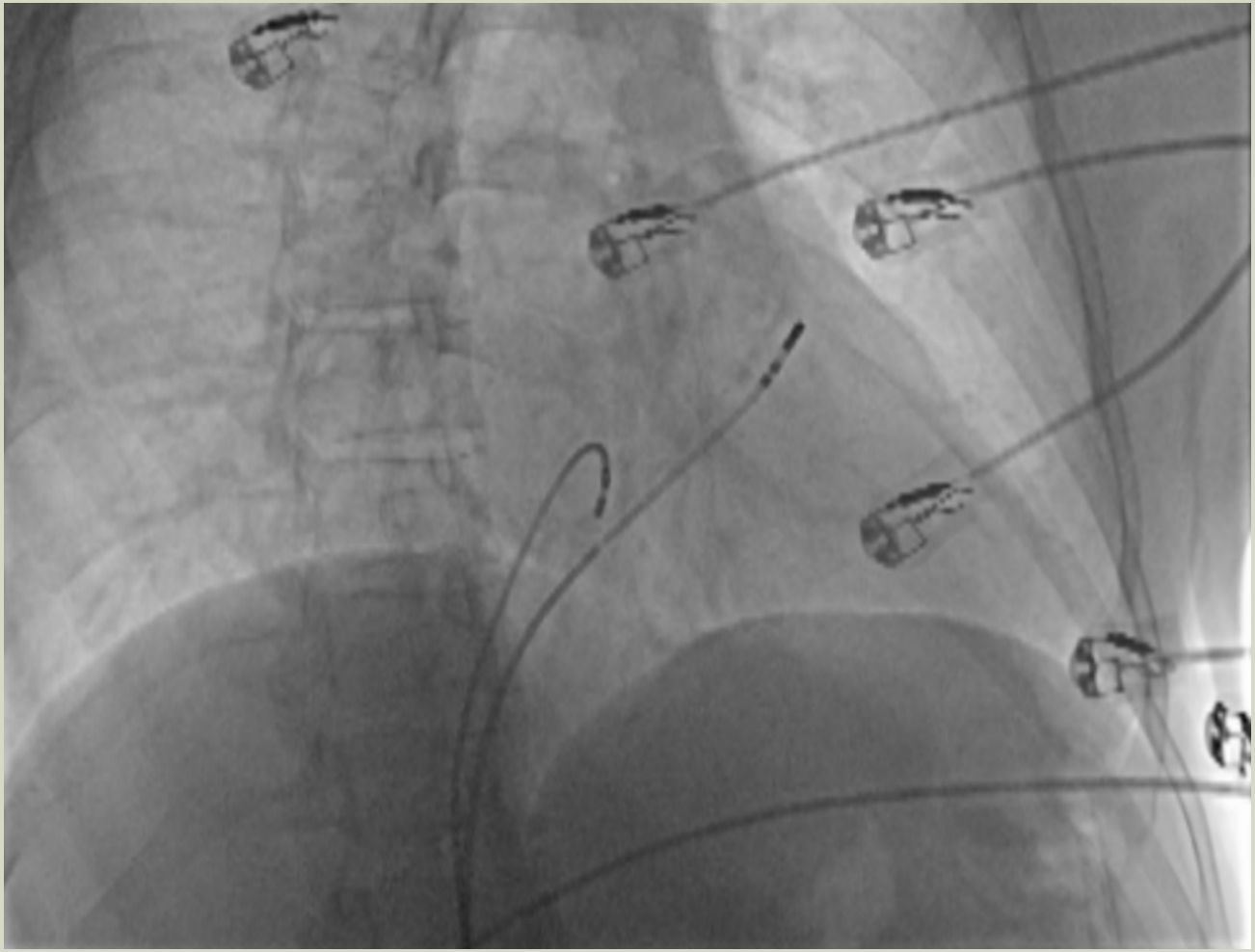

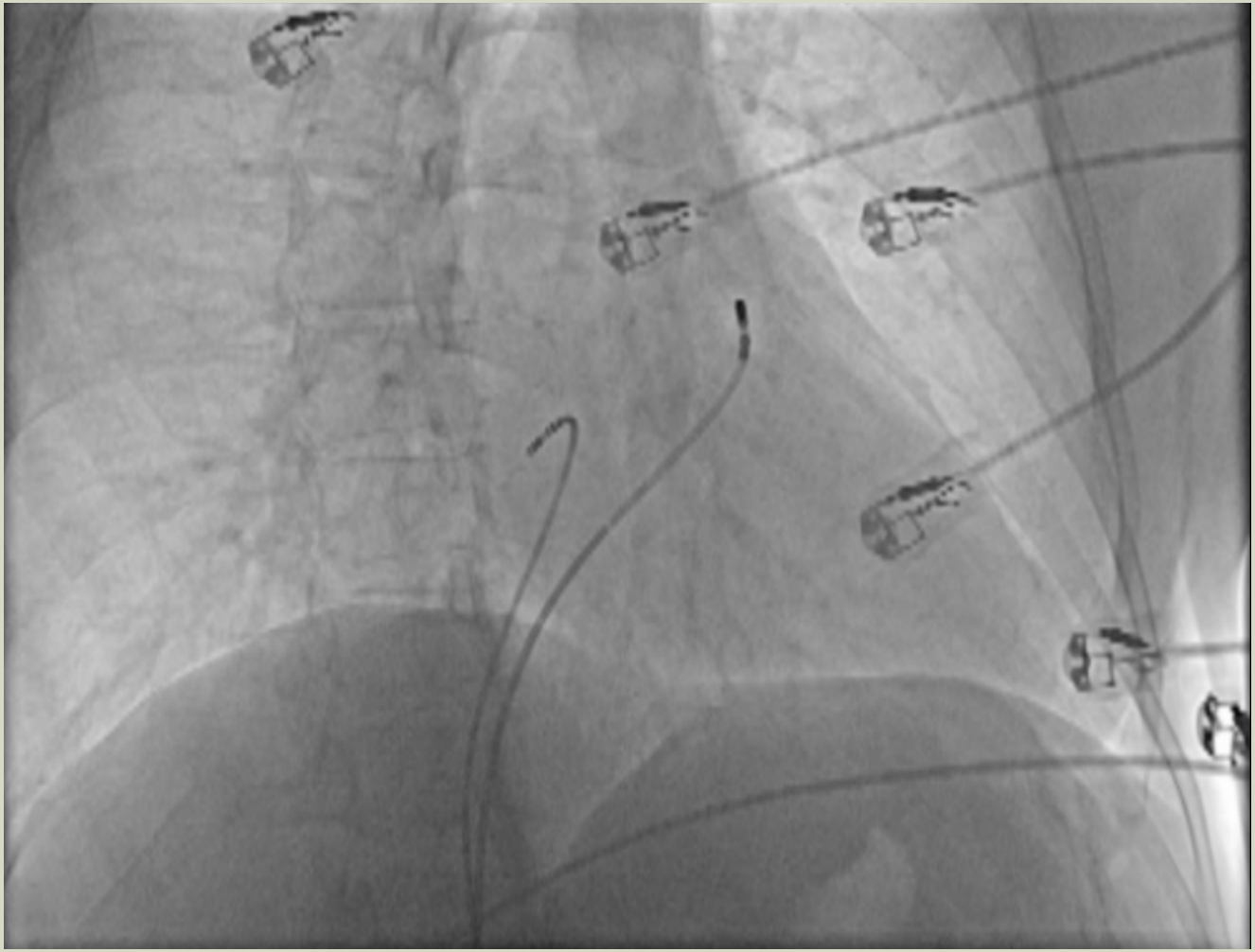

CASE 2

- 41 year old female
- Complaint of palpitation
- Incessant VT
- Failed ablation
- No organic heart disease

Name: Avcibasi Sibel
ID: 201201111112190

HR: 101 /Min
BP: 100/60 mmHg
METs: 1,0

11.01.2012 11:18:13

Exercise time: -
Stage: Pre 5:05
Load: 0,0 km/h 0,0%

	[mm]	[mV/s]		[mm]	[mV/s]
I	-0.6	0.1	V1	1.2	1.4
II	-2.8	-2.2	V2	0.6	2.1
III	-2.2	-2.3	V3	-0.3	1.9
aVR	1.7	1.0	V4	-1.7	-0.6
aVL	0.8	1.2	V5	-2.0	-1.3
aVF	-2.5	-2.2	V6	-2.1	-1.5

ST [mm] @ J+45ms
ST Slope [mV/s]

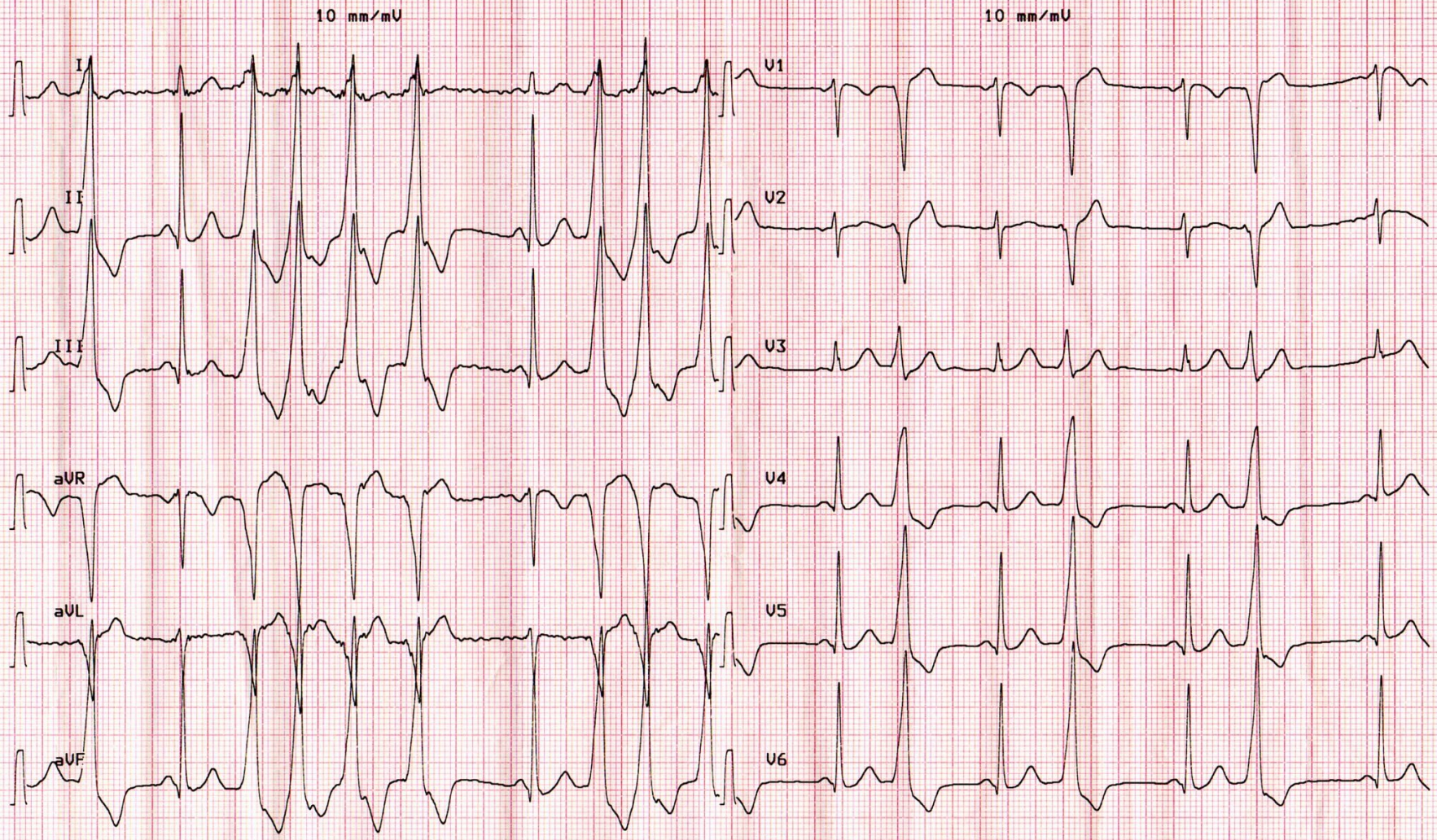

25 mm/s25 Hz F50 SBS SSF 11.01.2012 11:18:07 FATMA KEMAL TIMUCIN KALP HASTANESI CS-200 1.62

Name: Avcibasi Sibel
ID: 201201111112190

HR: 147 /Min
BP: 100/60 mmHg
METs: 4,6

11.01.2012 11:19:06

Exercise time: 0:47
Stage: 1 / 0:48
Load: 2,7 km/h 10,0%

	[mm]	[mV/s]		[mm]	[mV/s]
I	-0.6	0.0	V1	1.3	1.5
II	-3.8	-3.1	V2	1.4	2.6
III	-3.2	-3.1	V3	0.2	2.6
aVR	2.2	1.5	V4	-2.4	-1.7
aVL	1.3	1.6	V5	-2.9	-2.3
aVF	-3.5	-3.2	V6	-2.8	-2.4

ST [mm] @ J+45ms
ST Slope [mV/s]

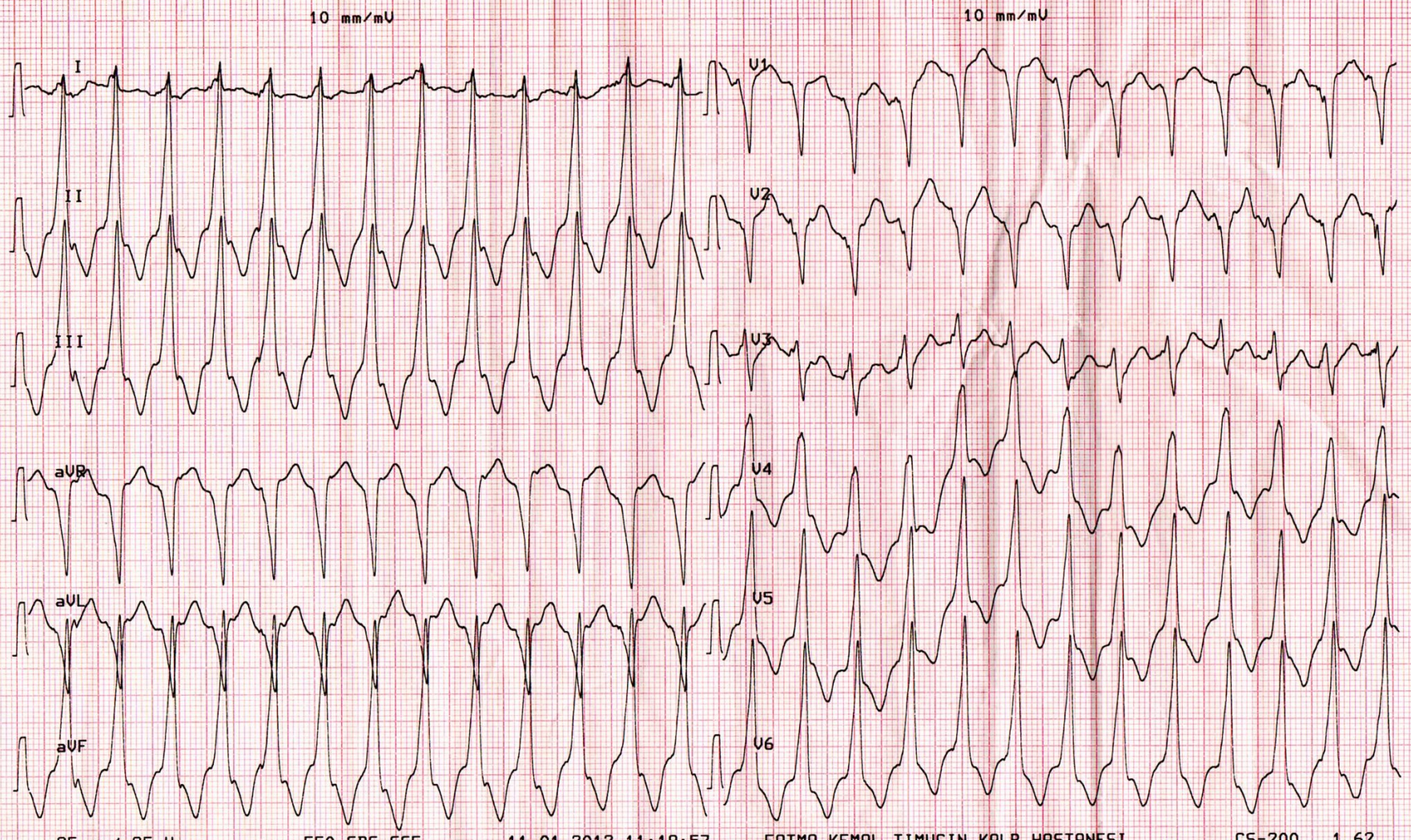

25 mm/s25 Hz F50 SBS SSF 11.01.2012 11:18:57 FATMA KEMAL TIMUCIN KALP HASTANESI CS-200 1.62

EP Tracer

Version WIN2000/XP : EPTRACER V0.77

Patient : avcibasi sibel / ves rf / 1980 File : C:\PAT\sibel avcibasi\SIBEL AVCIBASI.008
Comment :

Offline printed on : 08-06-2012 at 19:37:52
File recorded on : 18.01.2012 at 21:06:24 Time in file 0 msec

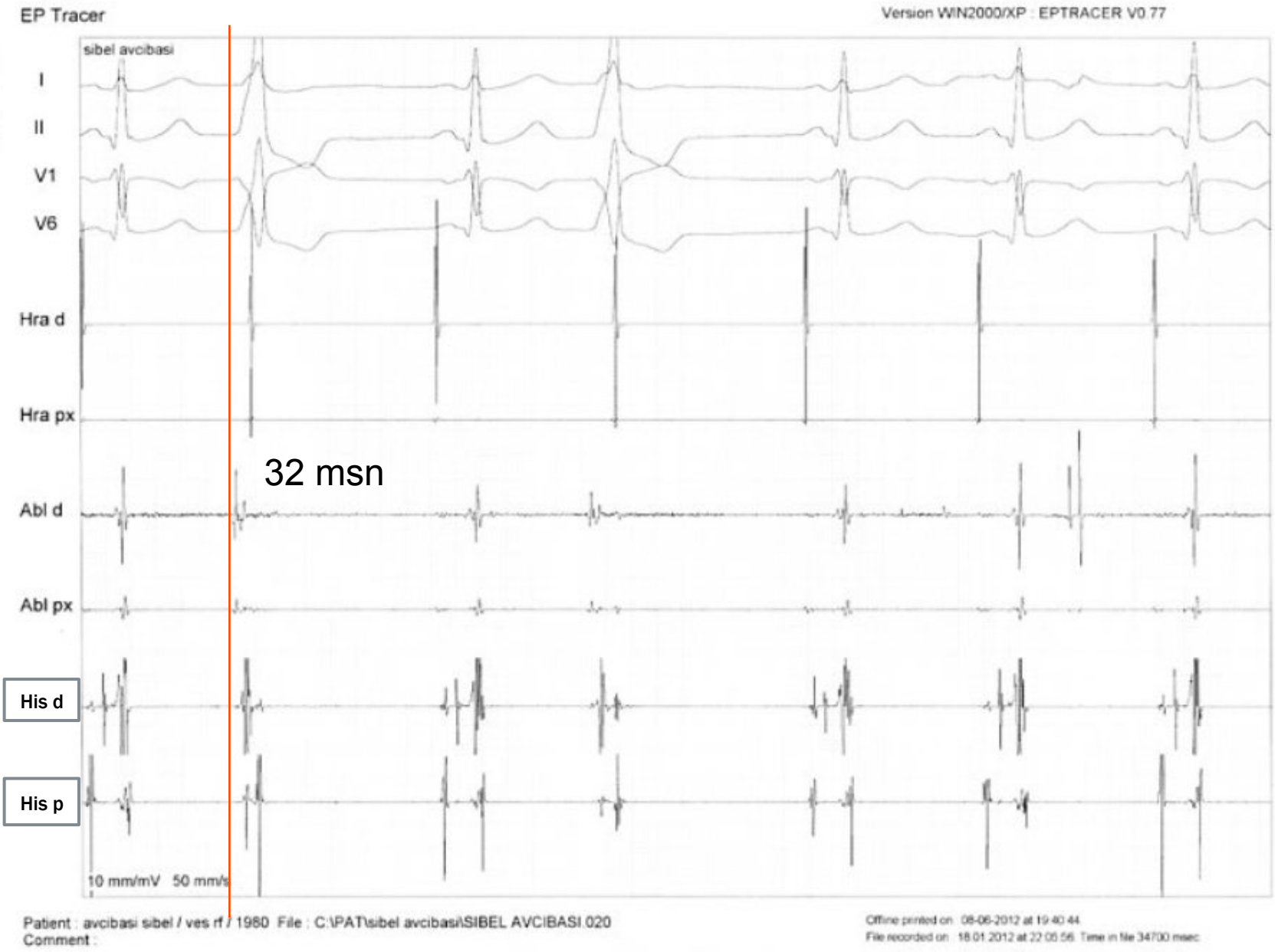
EP Tracer
Version WIN2000/XP : EPTRACER V0.77
sibel avcibasi
I
II
V1
V6
Hra d
Hra px
32 msn
Abl d
Abl px
His d
His p
10 mm/mV 50 mm/s
Patient : avcibasi sibel / ves rf / 1980 File : C:\PAT\sibel avcibasi\SIBEL AVCIBASI.020
Comment :
Offline printed on 08-06-2012 at 19:40:44
File recorded on 18.01.2012 at 22:05:56 Time in file 34700 msec

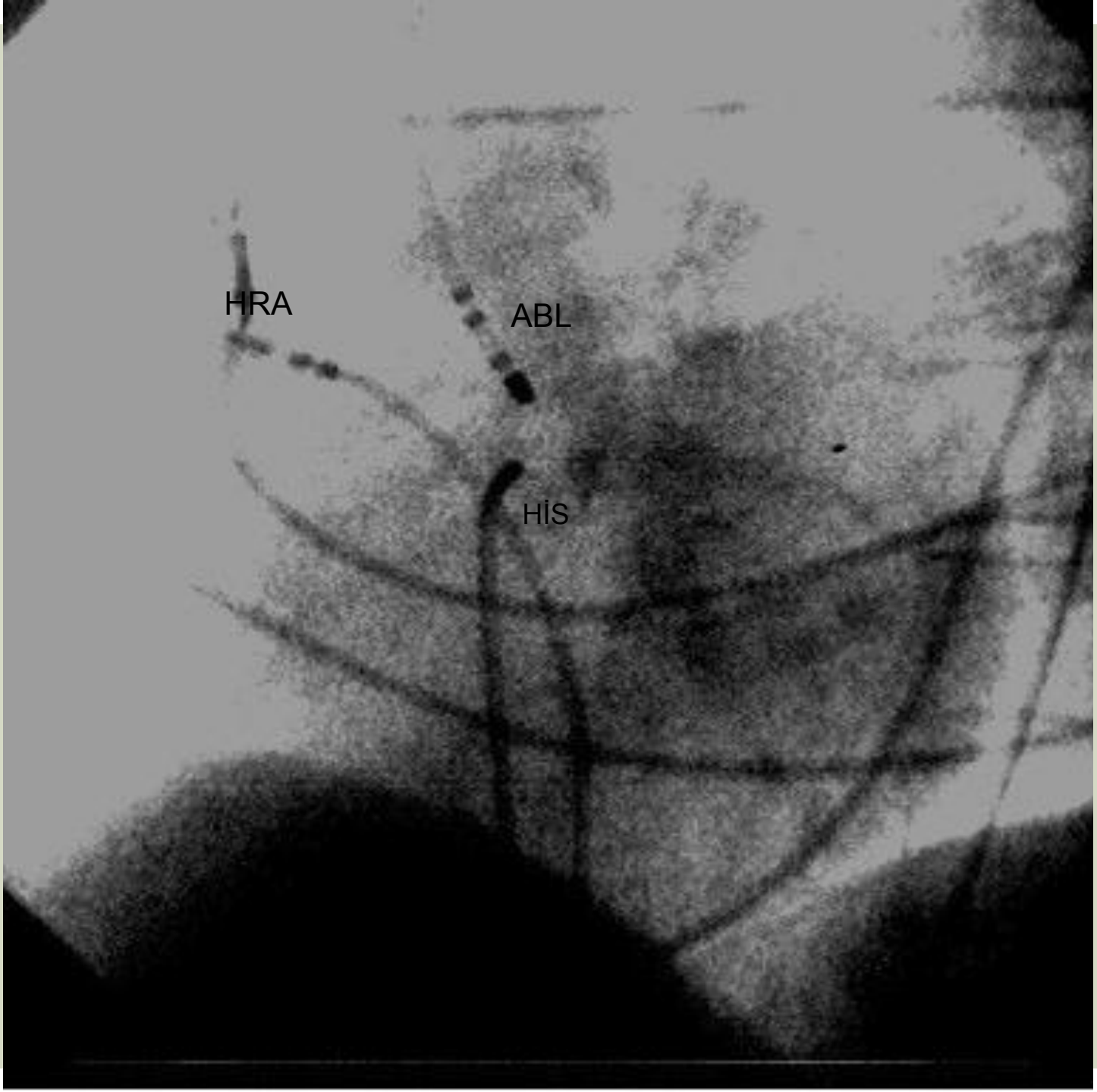
HRA
ABL
HİS

EP Tracer

Version WIN2000/XP : EPTRACER V0.77

CASE 3

- 9 years old boy
- Palpitation for 3 months
- Resistant to beta blokers
- ECHO: EF %45-50,Global mild hypokinesia
- ECG: Incessant wide QRS complex tachycardia

Sex:Male Birth Date: Years Medication:
Symptoms: cm kg mmHg 108 bpm
History:
10 mm/mV 25 mm/s Filter: H50 d 35 Hz 10 mm/mV

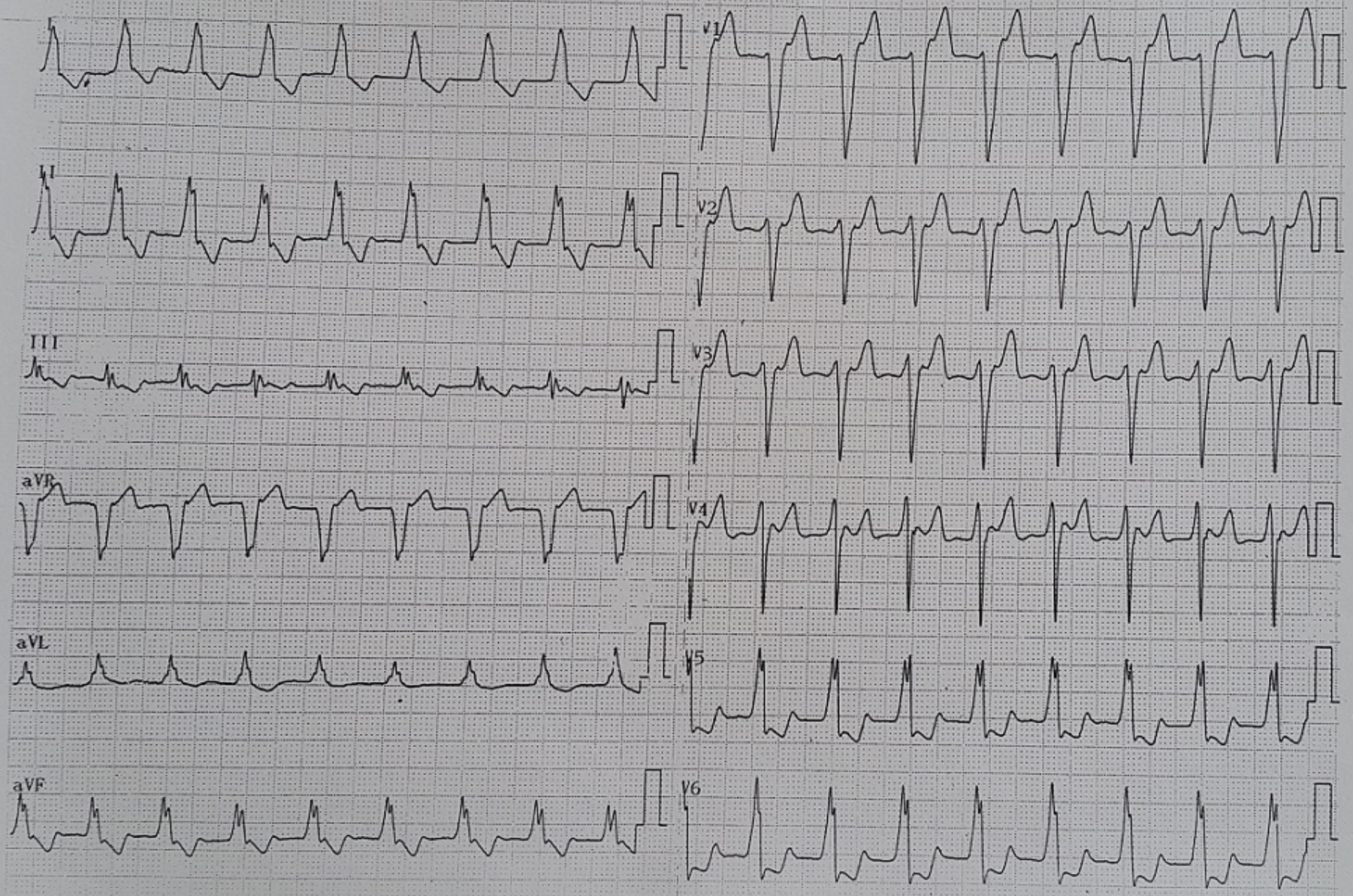

1350K 04-01 03-02 Dept.: Exam:KARDIN DOCHM HST

I
II
III
AVR
AVL
AVF
V1
V2
V3
V4
V5
V6

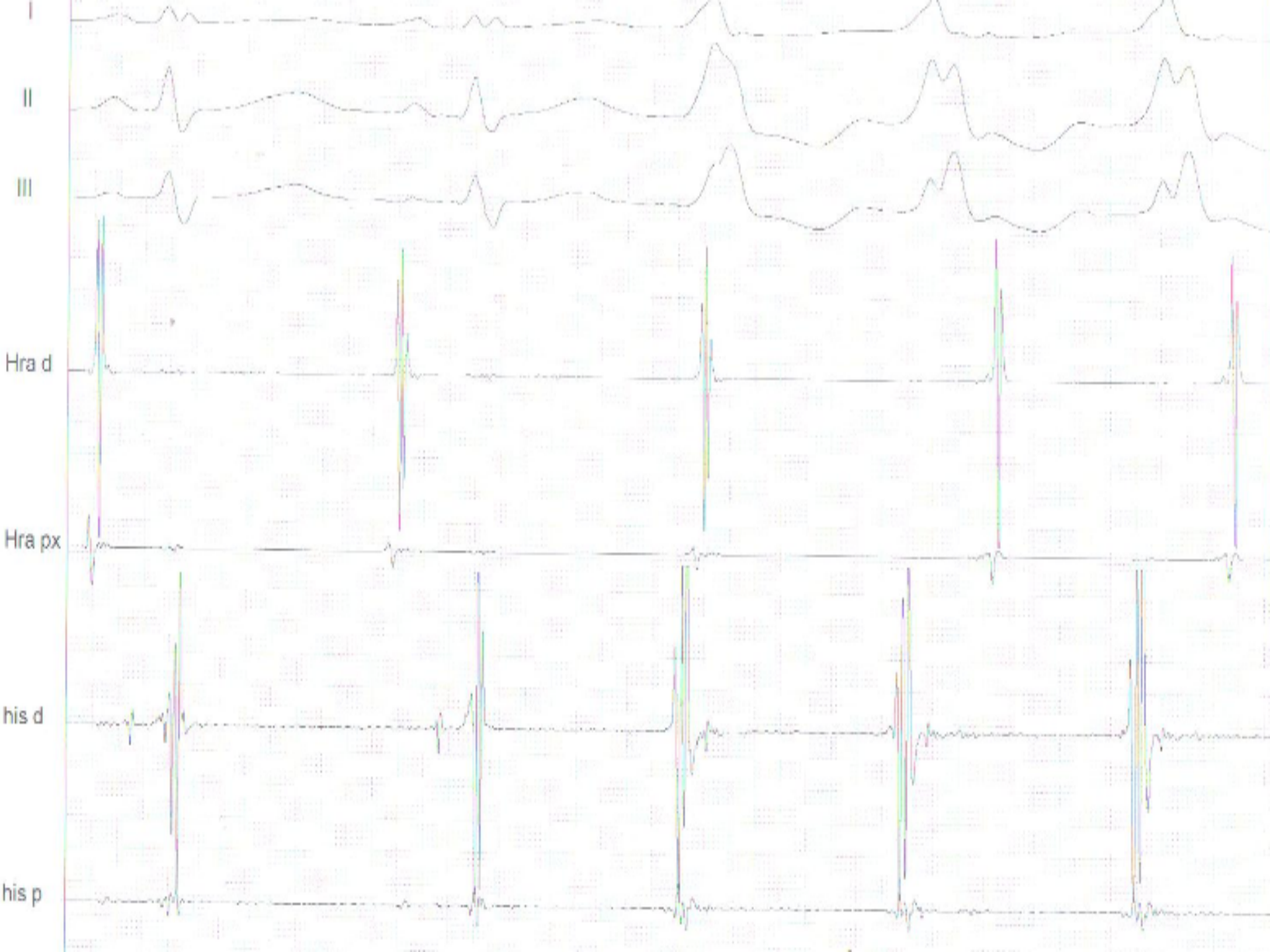
I
II
III
Hra d
Hra px
his d
his p

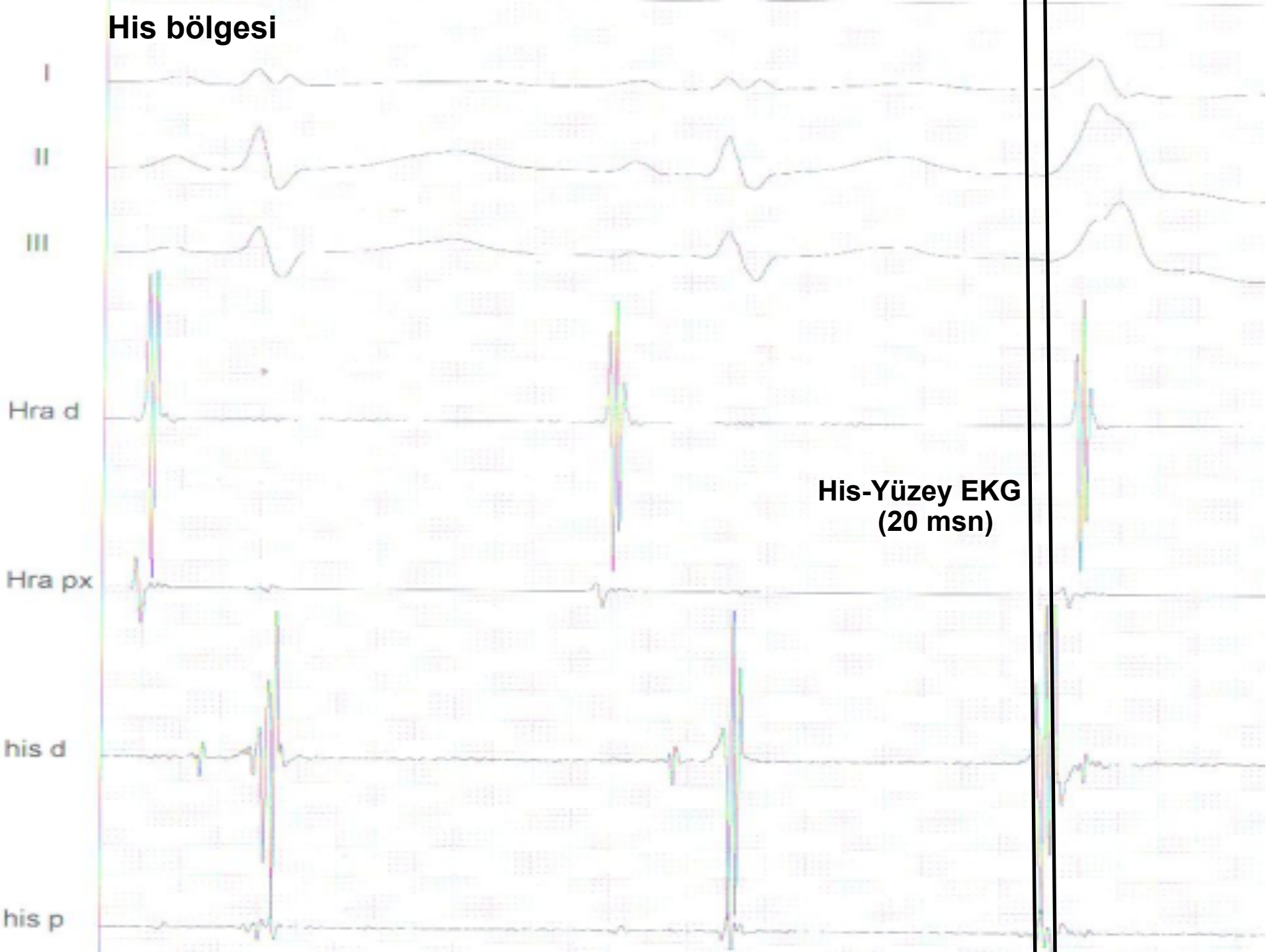
His bölgesi
I
II
III
Hra d
Hra px
his d
his p
His-Yüzey EKG
(20 msn)

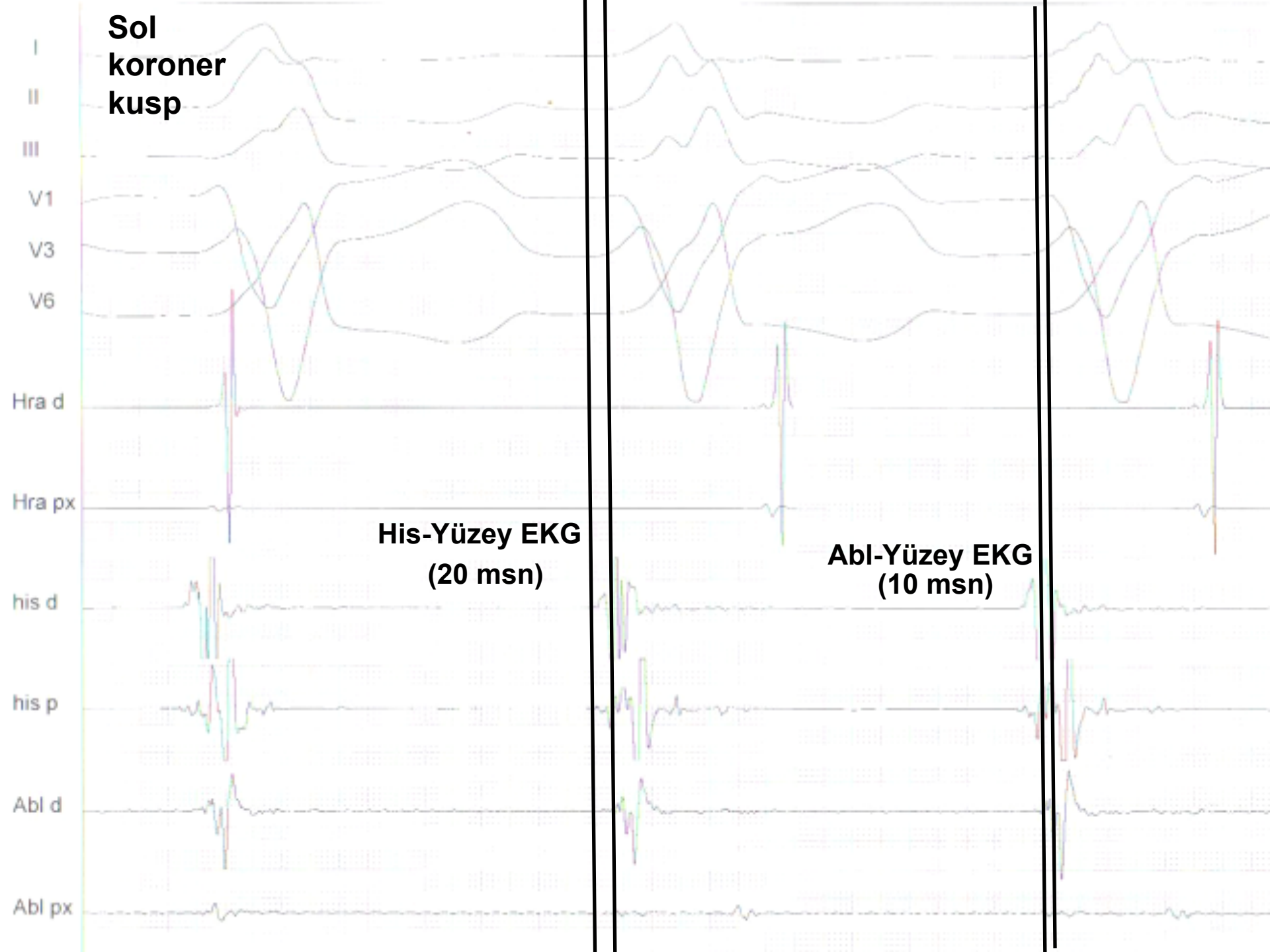
Sol koroner kusp
I
II
III
V1
V3
V6
Hra d
Hra px
his d
his p
Abl d
Abl px
His-Yüzey EKG (20 msn)
Abl-Yüzey EKG (10 msn)

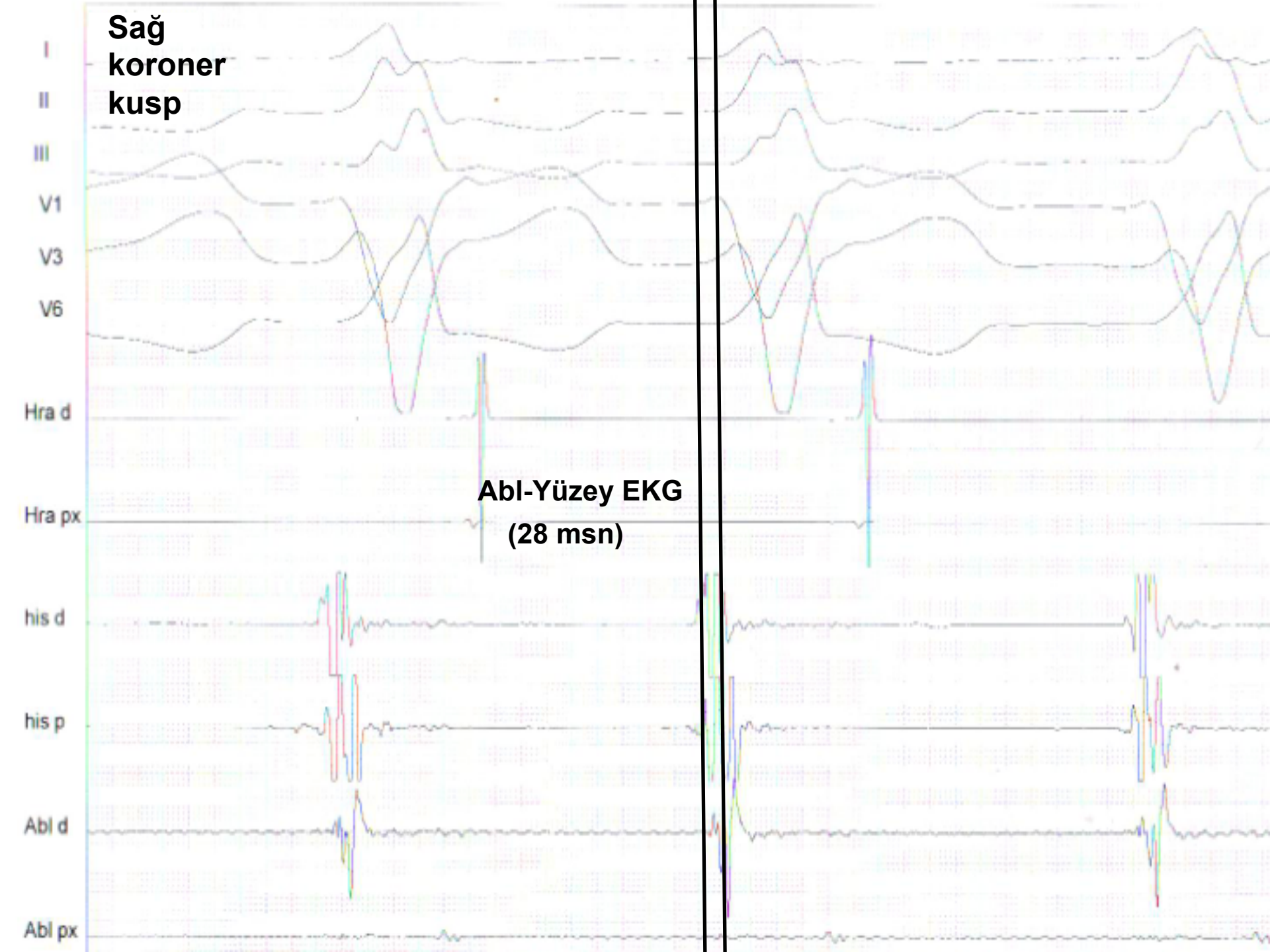
Sağ koroner kusp
I
II
III
V1
V3
V6
Hra d
Hra px
his d
his p
Abl d
Abl px
Abl-Yüzey EKG
(28 msn)

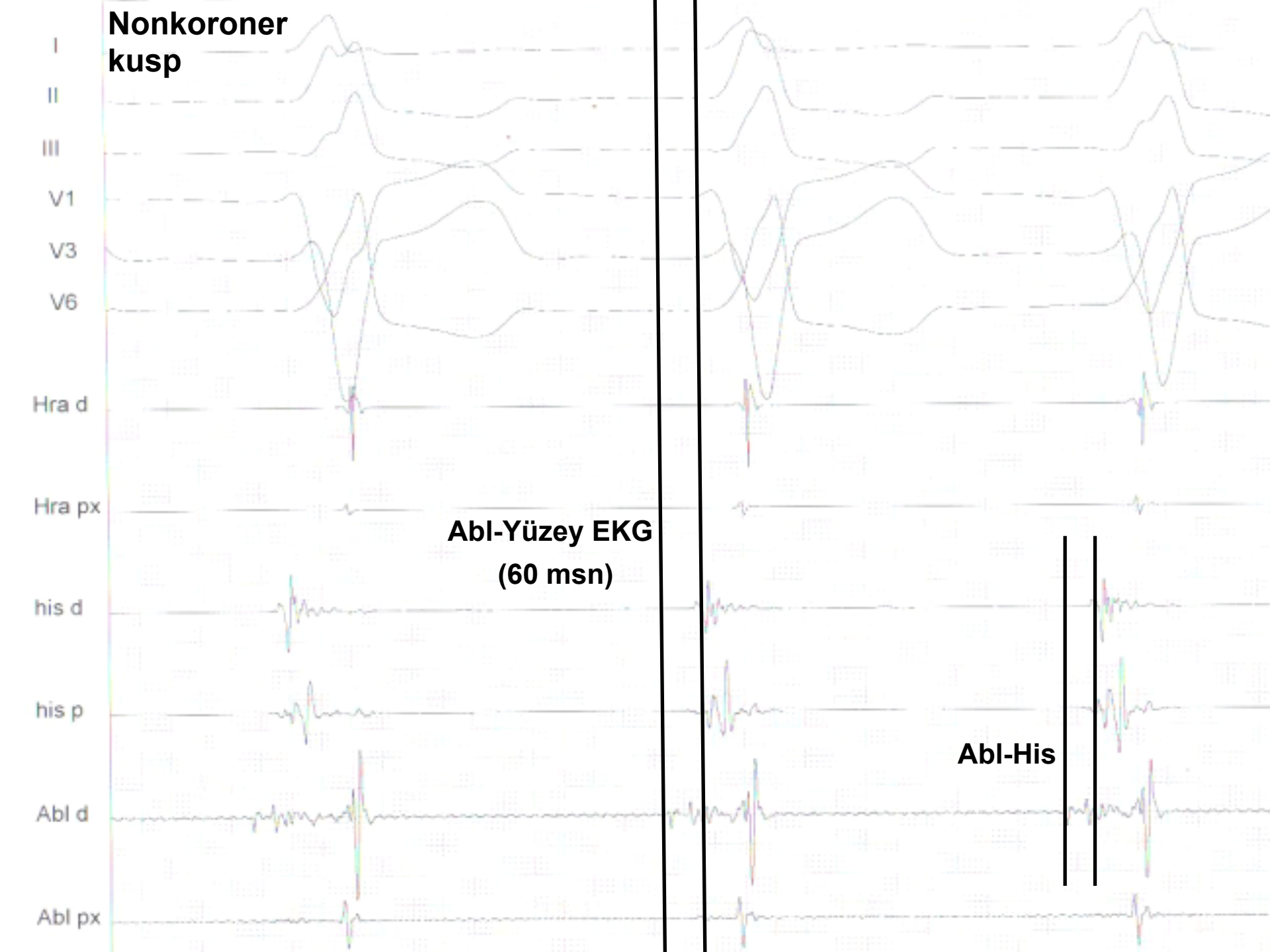
Nonkoroner kusp
I
II
III
V1
V3
V6
Hra d
Hra px
Abl-Yüzey EKG (60 msn)
his d
his p
Abl-His
Abl d
Abl px

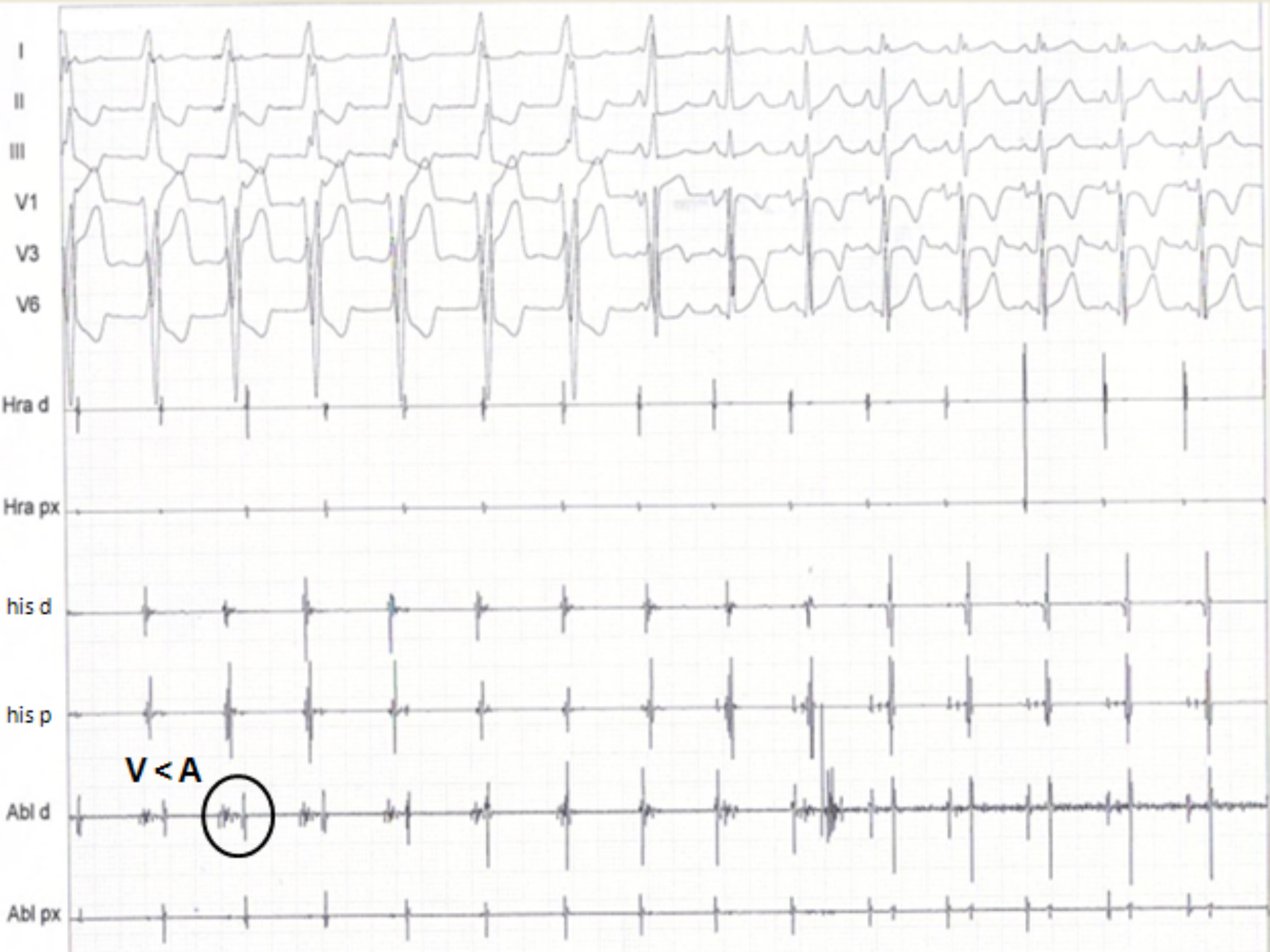
I
II
III
V1
V3
V6
Hra d
Hra px
his d
his p
V < A
Abl d
Abl px

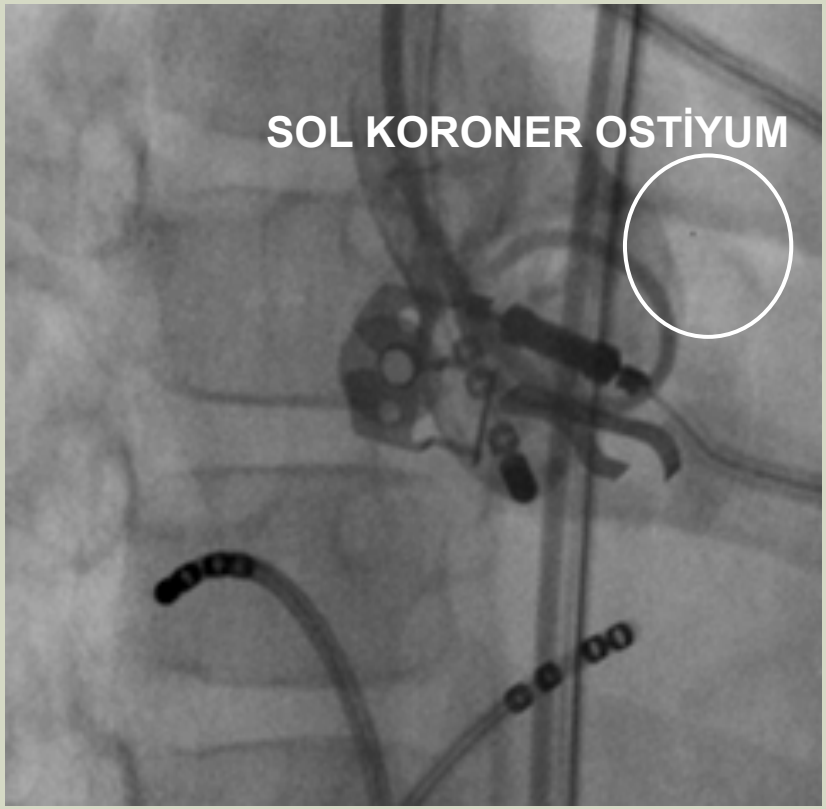
SOL KORONER OSTİYUM

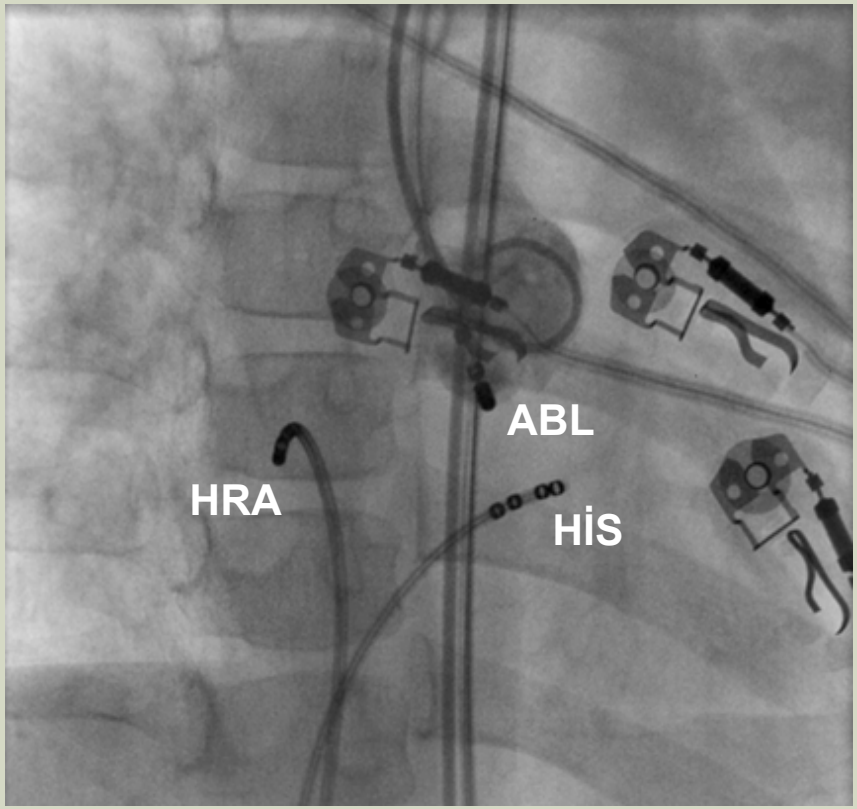
ABL
HRA
HİS

CASE 4

- 17 years old male
- Frequent palpitations for 2 years
- Frequent ectopy resistant to antiarrhythmics
- 6500 extra beats/24 hour
- No organic heart disease by echo and CMR

İŞLEM ÖNCESİ

AE

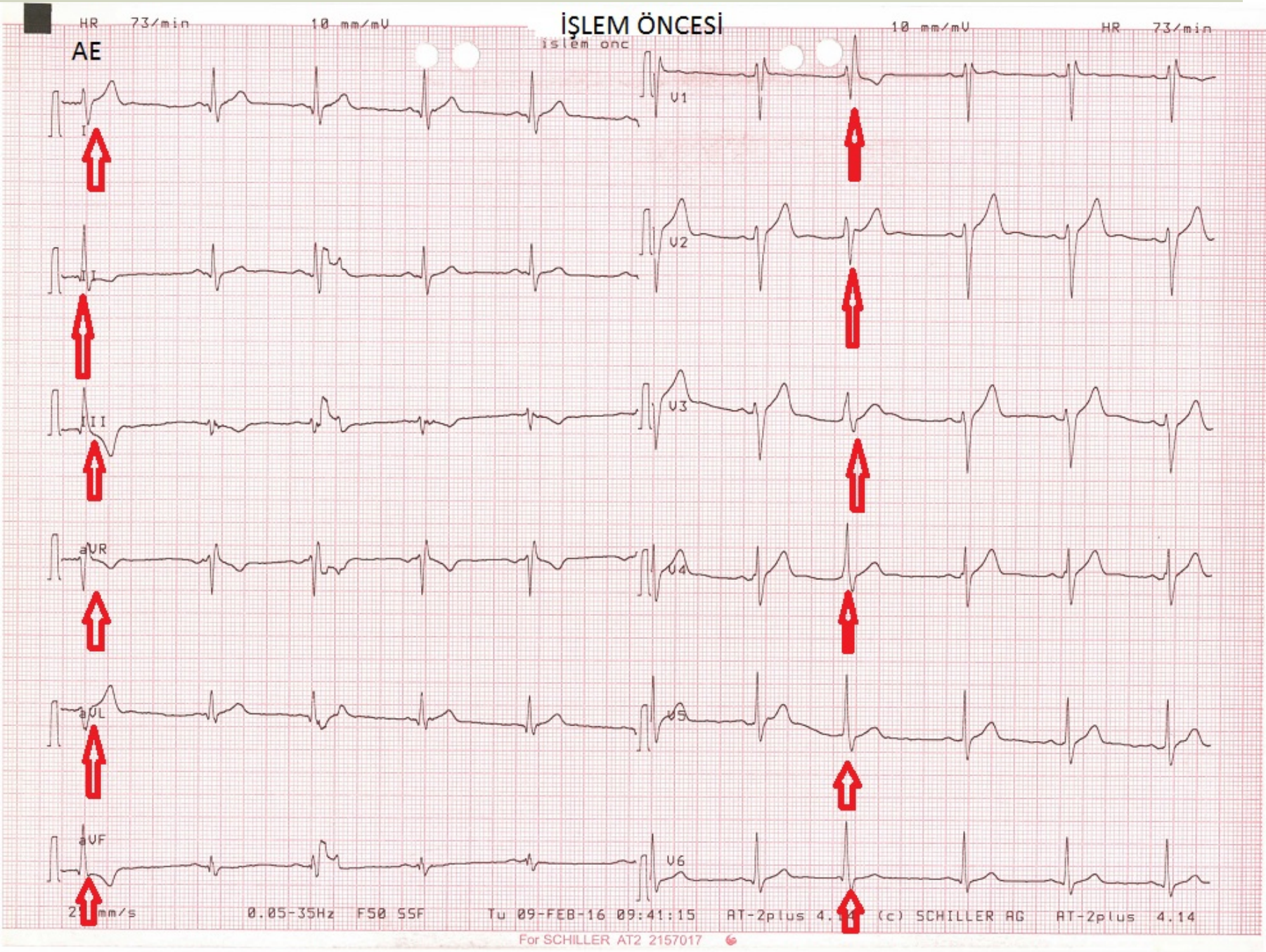

girin

Your Hospital Name in File HEADING.TXT

Version WIN2000/XP : EPTRACER V0.90

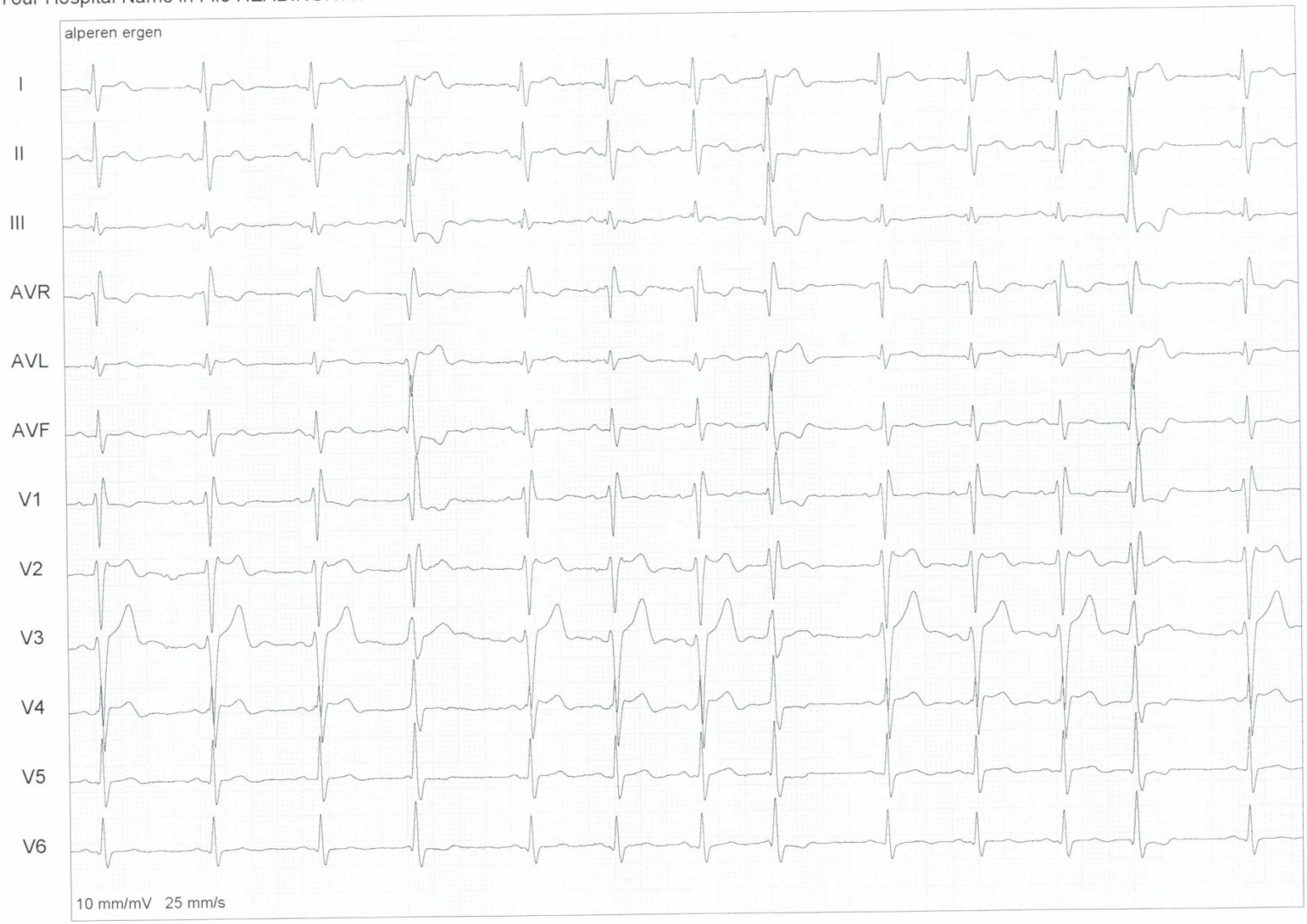

Patient : ergen alperen / ves / File : C:\PAT\alperen ergen\ALPEREN ERGEN.002
Comment :

Offline printed on : 31-01-2017 at 11:47:49.
File recorded on : 09.02.2016 at 10:34:54. Time in file 7528 msec.

Your Hospital Name in File HEADING.TXT

Version WIN2000/XP : EPTRACER V0.90

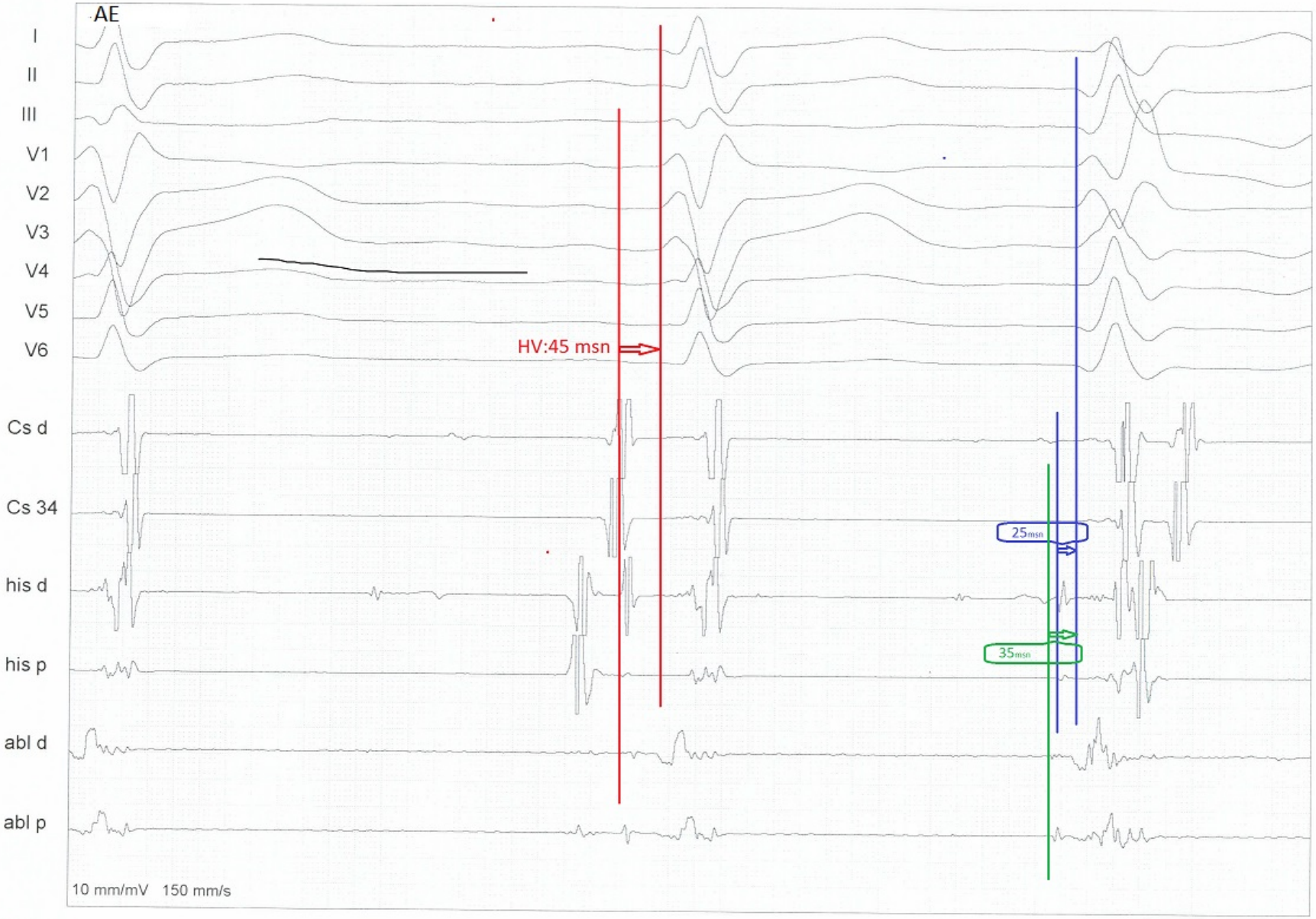

Patient : / ves / File : C:\PAT \32.000

Comment :

Offline printed on : 31-01-2017 at 11:57:01.

File recorded on : 09.02.2016 at 11:16:08. Time in file 7476 msec.

Your Hospital Name in File HEADING.TXT

Version WIN2000/XP : EPTRACER V0.90

Patient : ergen alperen / ves / File : C:\PAT\alperen ergen\RF.003
Comment :

Offline printed on : 31-01-2017 at 11:57:56.
File recorded on : 09.02.2016 at 11:26:08. Time in file 0 msec.

AE

İŞLEM SONRASI

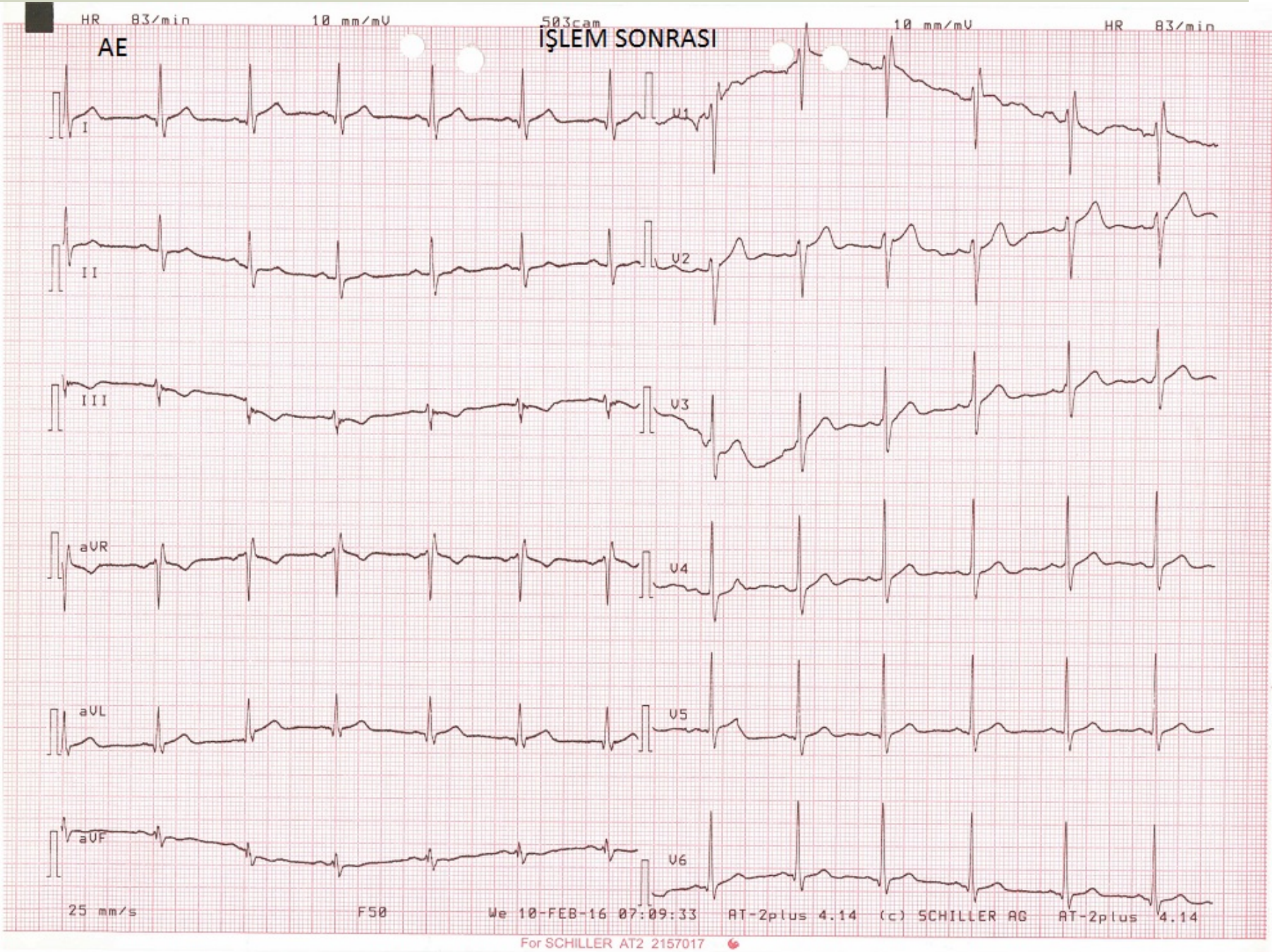

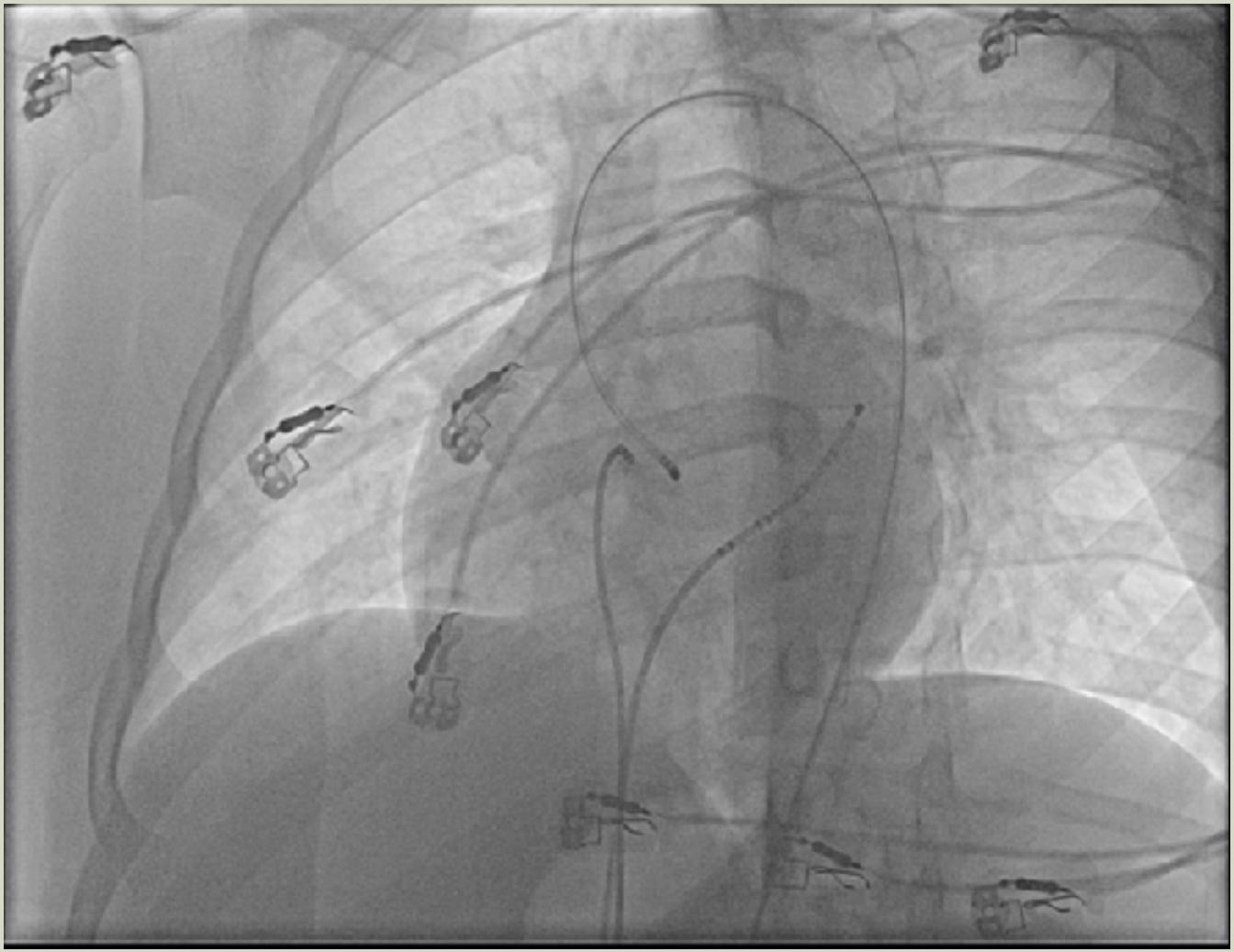

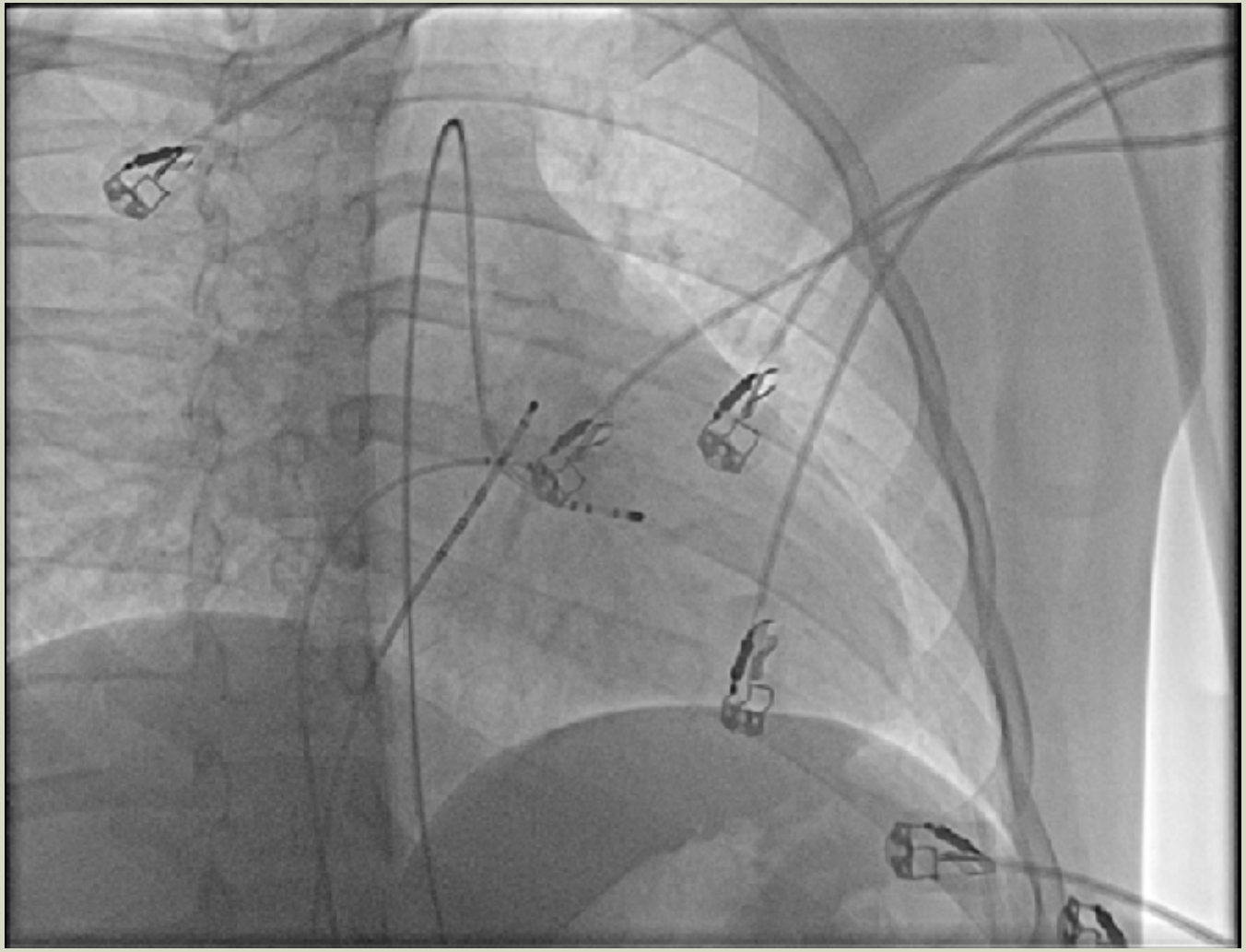

CASE 5

- 20 year old male
- Frequent palpitations and presncope for 20 days
- Incessant VT and frequent PVC resistant to antiarrhythmics
- Previous failed ablation 3 days ago
- Mildly dilated LV(59/42);RV looked normal on echo

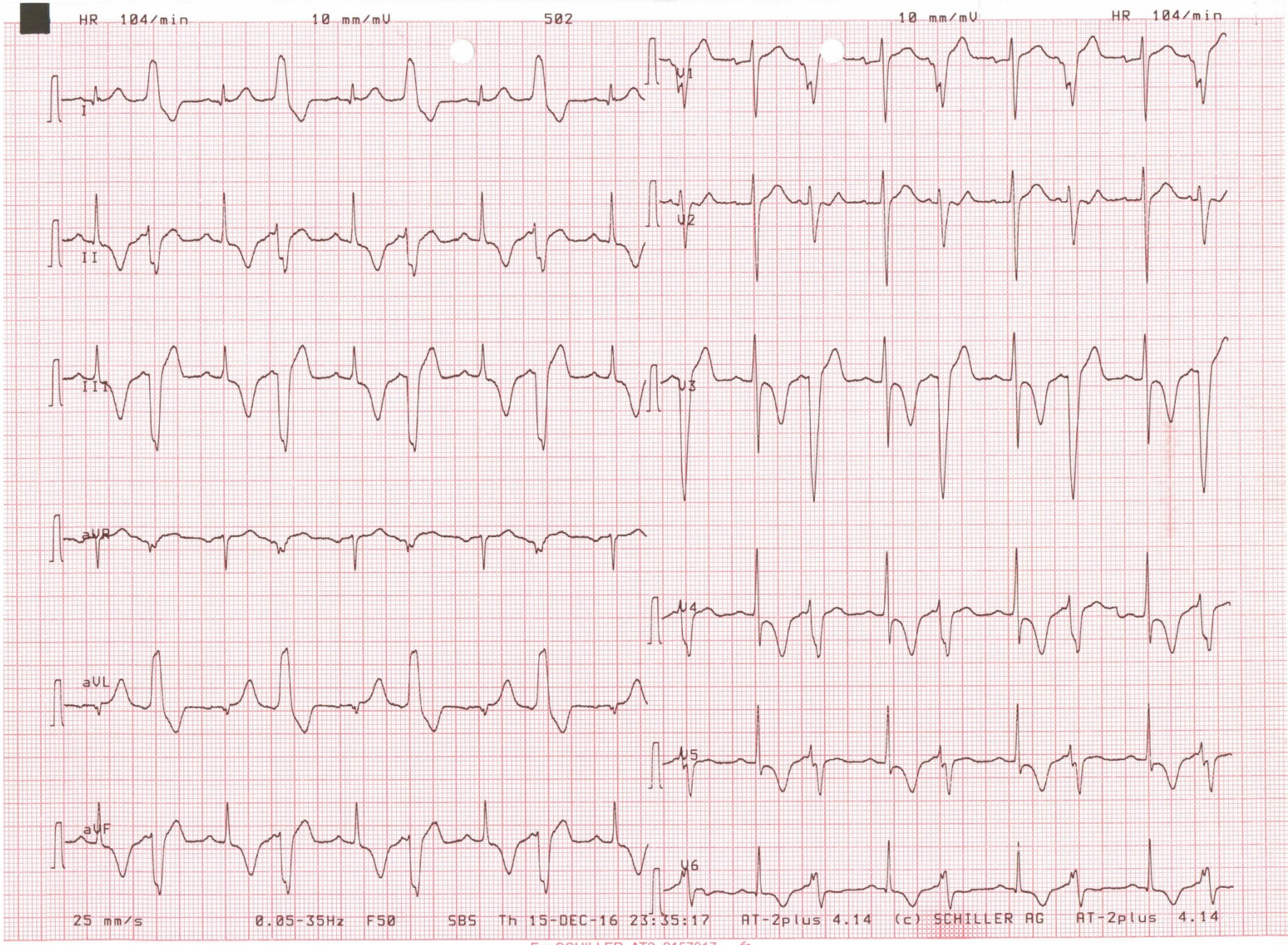

For SCHILLER AT2 2157017

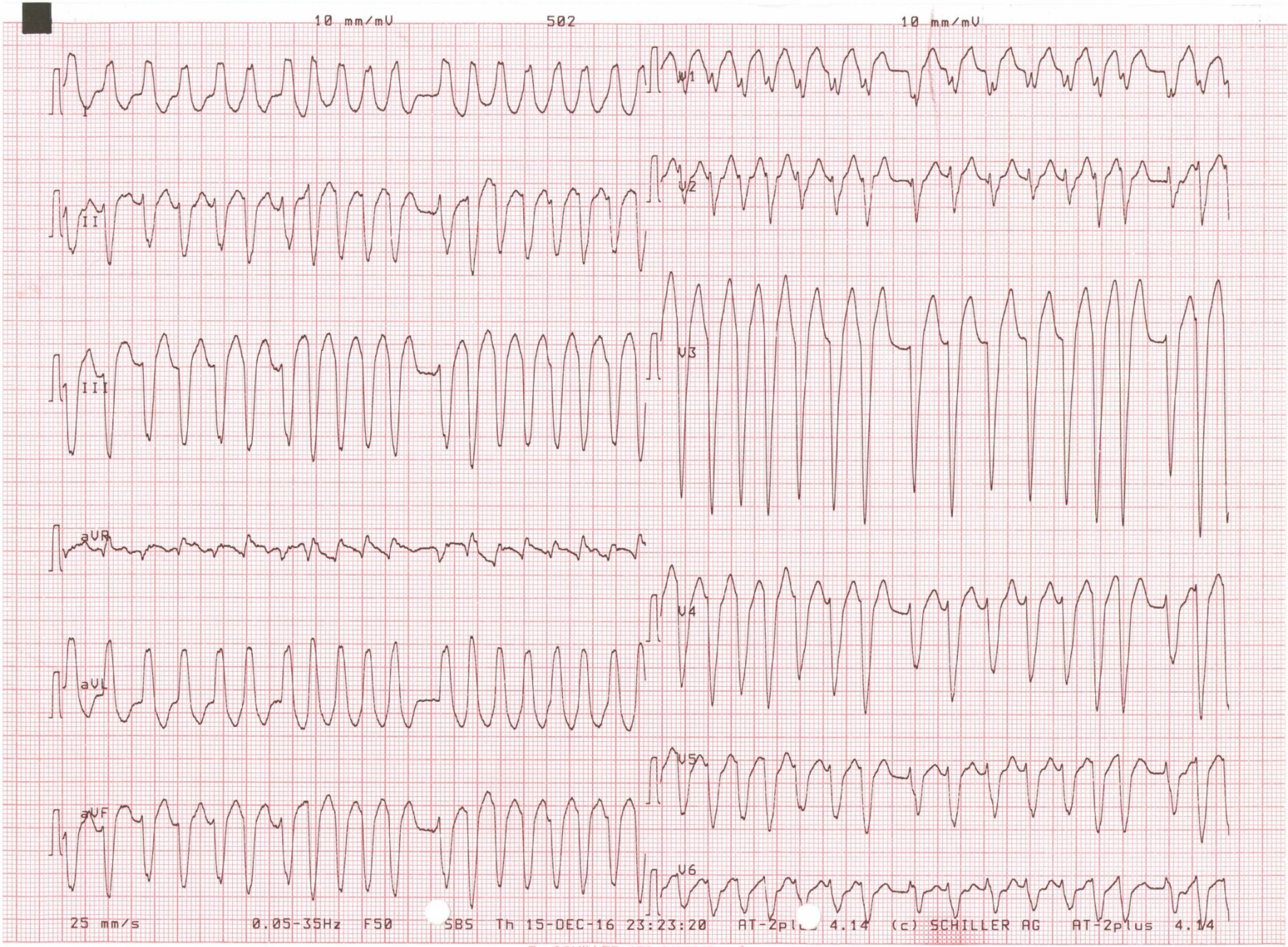
10 mm/mV
502
10 mm/mV
I
II
III
aVR
aVL
aVF
V1
V2
V3
V4
V5
V6
25 mm/s
0.05-35Hz F50
SBS Th 15-DEC-16 23:23:20
AT-2plus 4.14 (c) SCHILLER AG
AT-2plus 4.14
For SCHILLER AT2 2157017

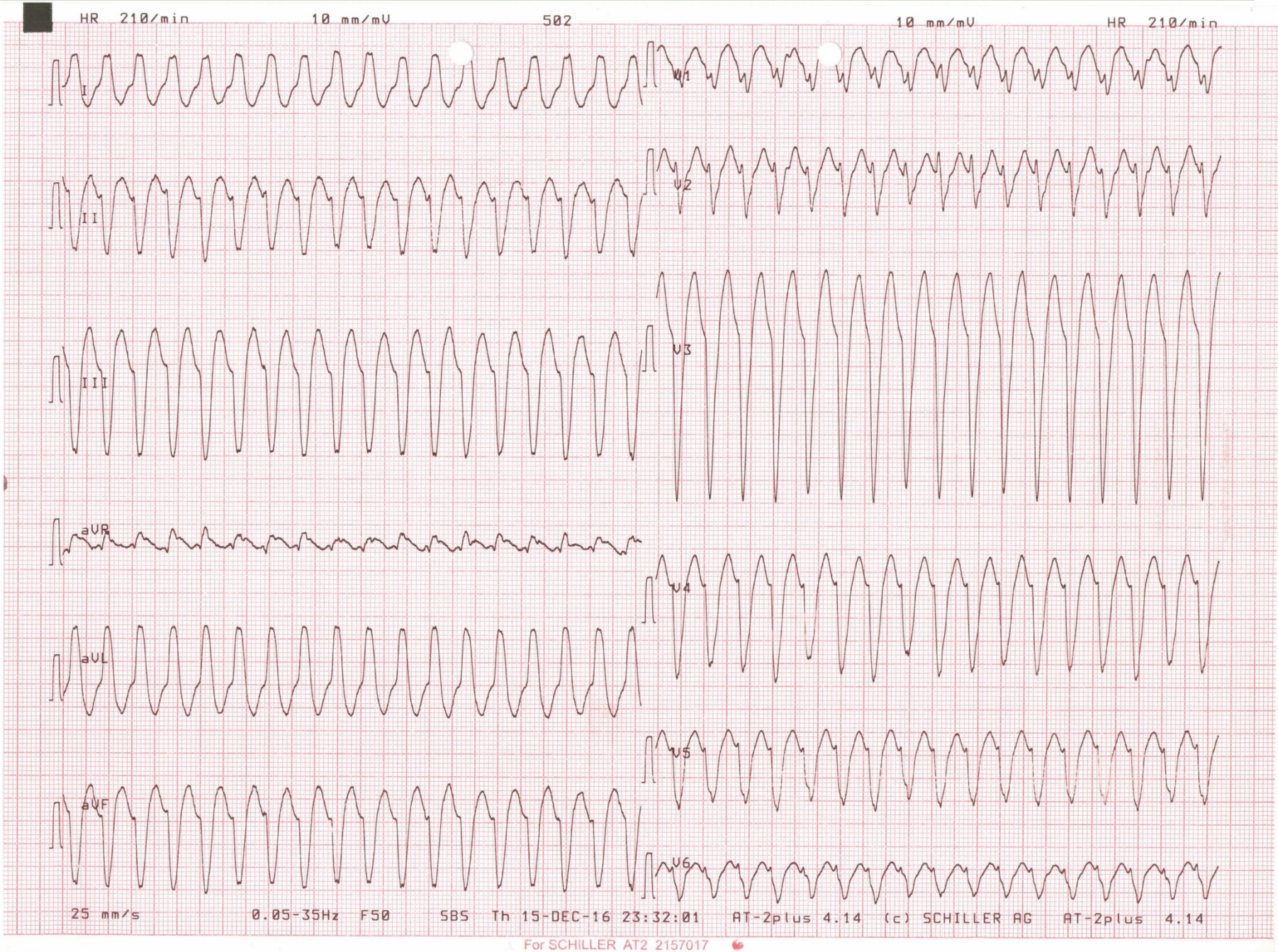
HR 210/min
10 mm/mV
502
10 mm/mV
HR 210/min
I
II
III
aVR
aVL
aVF
V1
V2
V3
V4
V5
V6
25 mm/s
0.05-35Hz F50
SBS Th 15-DEC-16 23:32:01
AT-2plus 4.14 (c) SCHILLER AG
AT-2plus 4.14
For SCHILLER AT2 2157017

Your Hospital Name in File HEADING.TXT

Version WIN2000/XP : EPTRACER V0.90

Patient : irgi nihat / vt / File : C:\PAT\nihat irgi\NIHAT IRGI.001
Comment :

Offline printed on : 31-01-2017 at 11:36:34
File recorded on : 17.12.2016 at 07:17:42. Time in file 41232 msec.

35

Your Hospital Name in File HEADING.TXT

Version WIN2000/XP : EPTRACER V0.90

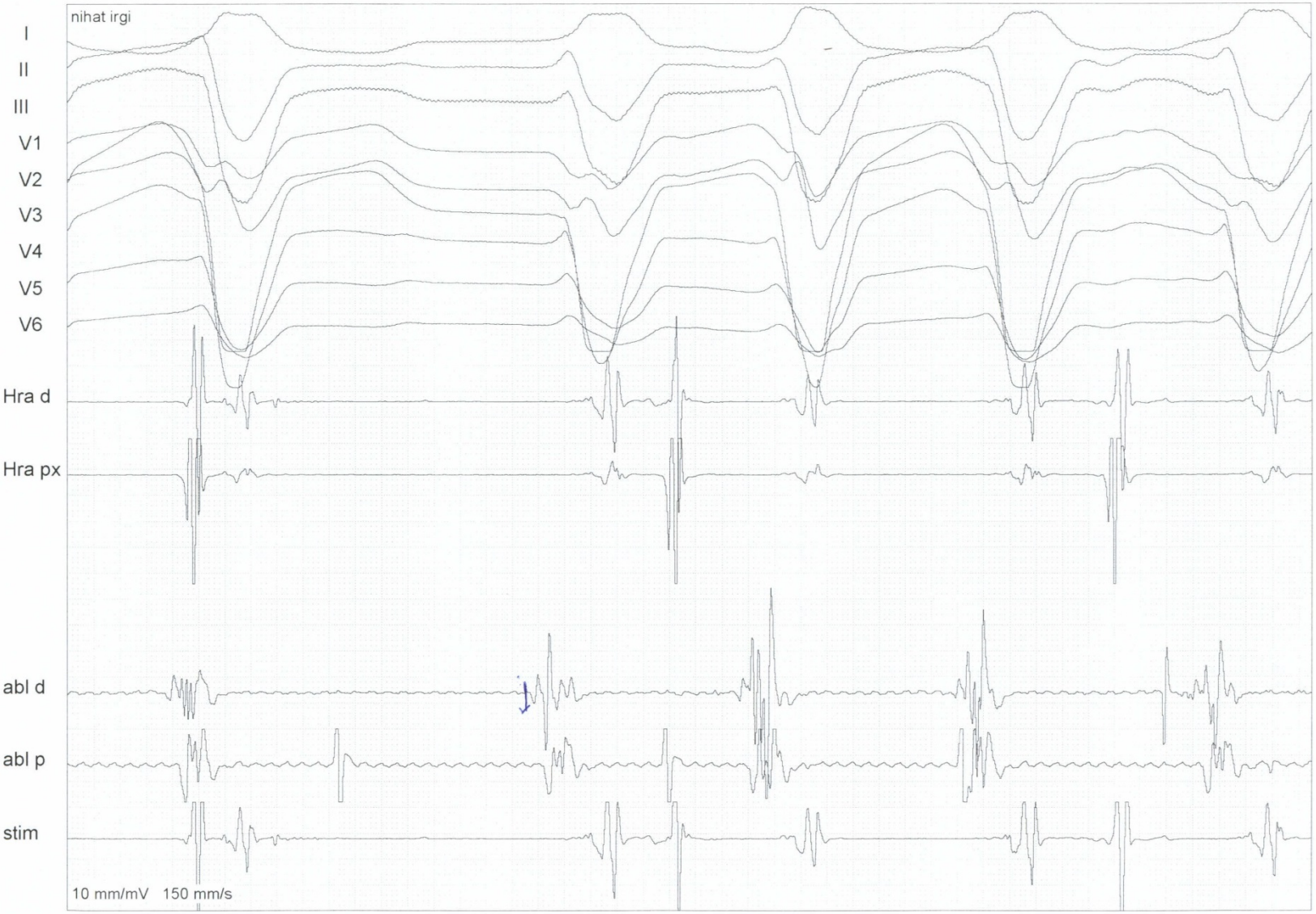

Patient : irgi nihat / vt / File : C:\PAT\nihat irgi\RF DRDU.001
Comment :

Offline printed on : 31-01-2017 at 11:42:30.
File recorded on : 17.12.2016 at 07:57:48. Time in file 51588 msec.

Your Hospital Name in File HEADING.TXT
Version WIN2000/XP : EPTRACER V0.90
Ni
I
II
III
V1
V2
V3
V4
V5
V6
Hra d
Hra px
35msn
abl d
abl p
stim
10 mm/mV 150 mm/s
Patient : Ni
Comment :
/ vt / File : C:\PAT\
RF DRDU.001
Offline printed on : 31-01-2017 at 11:42:30.
File recorded on : 17.12.2016 at 07:57:48. Time in file 51588 msec.

Your Hospital Name in File HEADING.TXT

Version WIN2000/XP : EPTRACER V0.90

Patient : irgi nihat / vt / File : C:\PAT\nihat irgi\RF DRDU.001
Comment :

Offline printed on : 31-01-2017 at 11:38:47.
File recorded on : 17.12.2016 at 07:57:48. Time in file 50034 msec.

Your Hospital Name in File HEADING.TXT

Version WIN2000/XP : EPTRACER V0.90

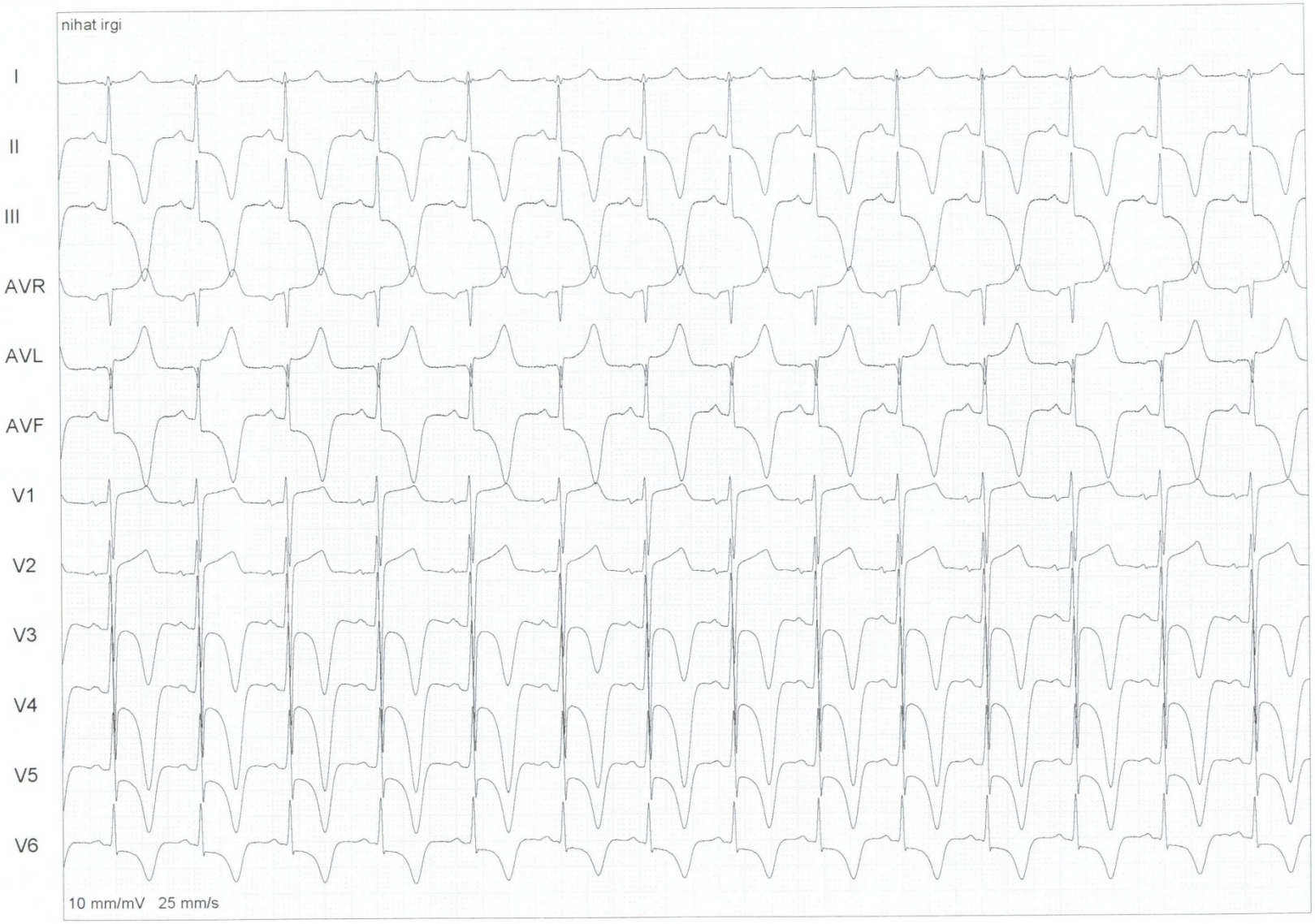

Patient : irgi nihat / vt / File : C:\PAT\nihat irgi\RF.008
Comment :

Offline printed on : 31-01-2017 at 11:41:58.
File recorded on : 17.12.2016 at 08:19:00. Time in file 36288 msec.

Patient Information | Image Processing | Channel Setup | Cardiac Mapping

2017-01-30 14:38:55

Columbus

IRGI NIHAT
- Study-1
  - Map-1
- Study-2

AP PA LAO RAO LL RL INF SUP

0.71cm 101cm², 31ml
LAO:97.1° CAU:23.0°

-15ms
-113ms

AP PA LAO RAO LL RL INF SUP

0.71cm 101cm², 31ml
LAO:45.0° CRA:0.0°

LAO

-15ms
-113ms

III 1.00
M1-M2 1.00
-190

Point | Ref

	ID	Lat	Uni	Bi	Tag	Type	C
27	031	-52	7.16	5.21		Normal	
28	032	-45	7.43	6.15		Normal	
29	033	-64	6.00	7.06		Normal	
30	034	-47	5.24	1.88		Normal	
31	035	-51	5.79	1.43		Normal	
32	036	-82	5.18	6.19		Normal	
33	037	-55	5.24	5.69		Normal	
34	038	-53	5.14	5.52		Normal	
35	040	-64	6.05	6.29		Normal	
36	041	-58	5.28	3.61		Normal	
37	042	-59	5.37	1.31		Normal	
38	043	-100	7.48	1.99		Normal	
39	044	-94	7.32	2.62		Normal	
40	045	-58	3.85	1.20		Normal	
41	047	-50	3.05	3.03		Normal	
42	048	-67	6.79	2.91		Normal	
43	049	-70	6.89	5.35		Normal	
44	050	-67	6.43	6.45		Normal	
45	051	-61	6.40	3.82		Normal	
46	052	-61	6.80	5.63		Normal	
47	053	-84	6.52	4.16		Normal	
48	054	-87	6.62	4.42		Normal	

Recycle Bin

	ID	Lat	Uni	Bi	Tag	Type	Comm
1	001	-139	6.52	6.09		No···	
2	003	-16	6.58	3.06		No···	
3	011	-45	6.78	6.25		No···	
4	016	-9	2.38	1.23		No···	
5	039	-67	6.33	5.19		No···	
6	046	-40	2.77	0.91		No···	
7	084	-89	7.51	2.69	ABL	Lo···	

100mm/s 1000 Pacing: None RF Num:14 RF Time:18:14 RF Points:129 ECG Distortion

<< -9 -8 -7 -6 -5 -4 -3 -2 -1 0 >>

1.00
III 1.00
V1 1.00
V5 1.00
M1-M2 1.00

285 CL(ms)

LAT: 17.0ms
CL: 34%
LOC: 2.6mm

-52 LAT(ms) 7.16 Uni(mV) 5.21 Bi(mV)

Error

Continue | Show Detail

CASE 6

- 26 year old male
- Frequent palpitations for 3 years
- Frequent PVC resistant to antiarrhythmics
- 13500 PVC/24 hour
- No organic heart disease

EP Tracer

Version WIN2000/XP : EPTRACER V0.77

Patient : cebeci metin / vt / 1984 File : C:\PAT\metin cebeci\HIS.000
Comment :

Offline printed on : 13-01-2011 at 16:08:56
File recorded on : 06.01.2011 at 22:34:32 Time in file 0 msec

EP Tracer

Version WIN2000/XP : EPTRACER V0.77

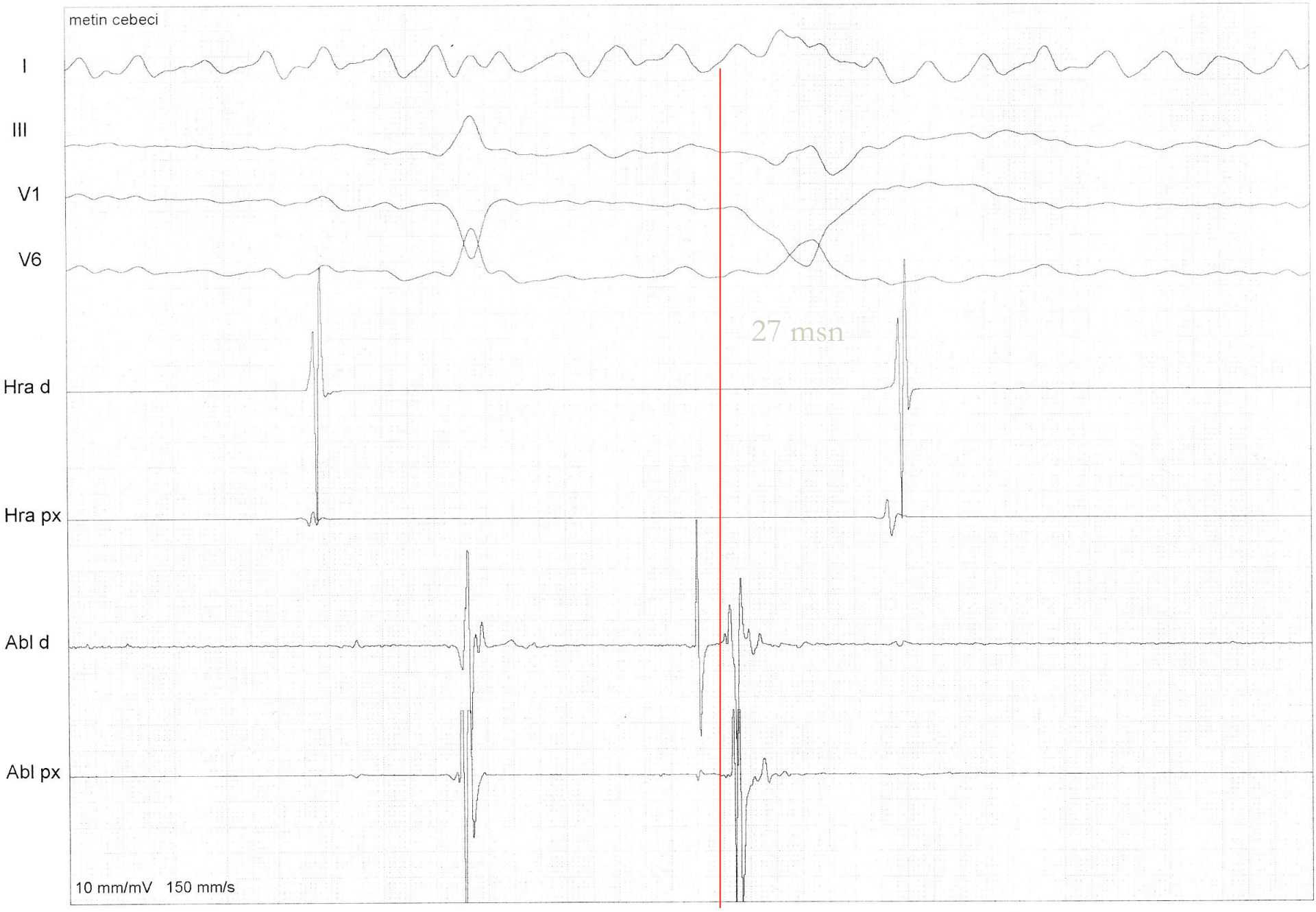

Patient : cebeci metin / vt / 1984 File : C:\PAT\metin cebeci\RF.000

Offline printed on : 13-01-2011 at 17:26:20.
File recorded on : 06.01.2011 at 23:25:16. Time in file 35710 msec

EP Tracer

Version WIN2000/XP : EPTRACER V0.77

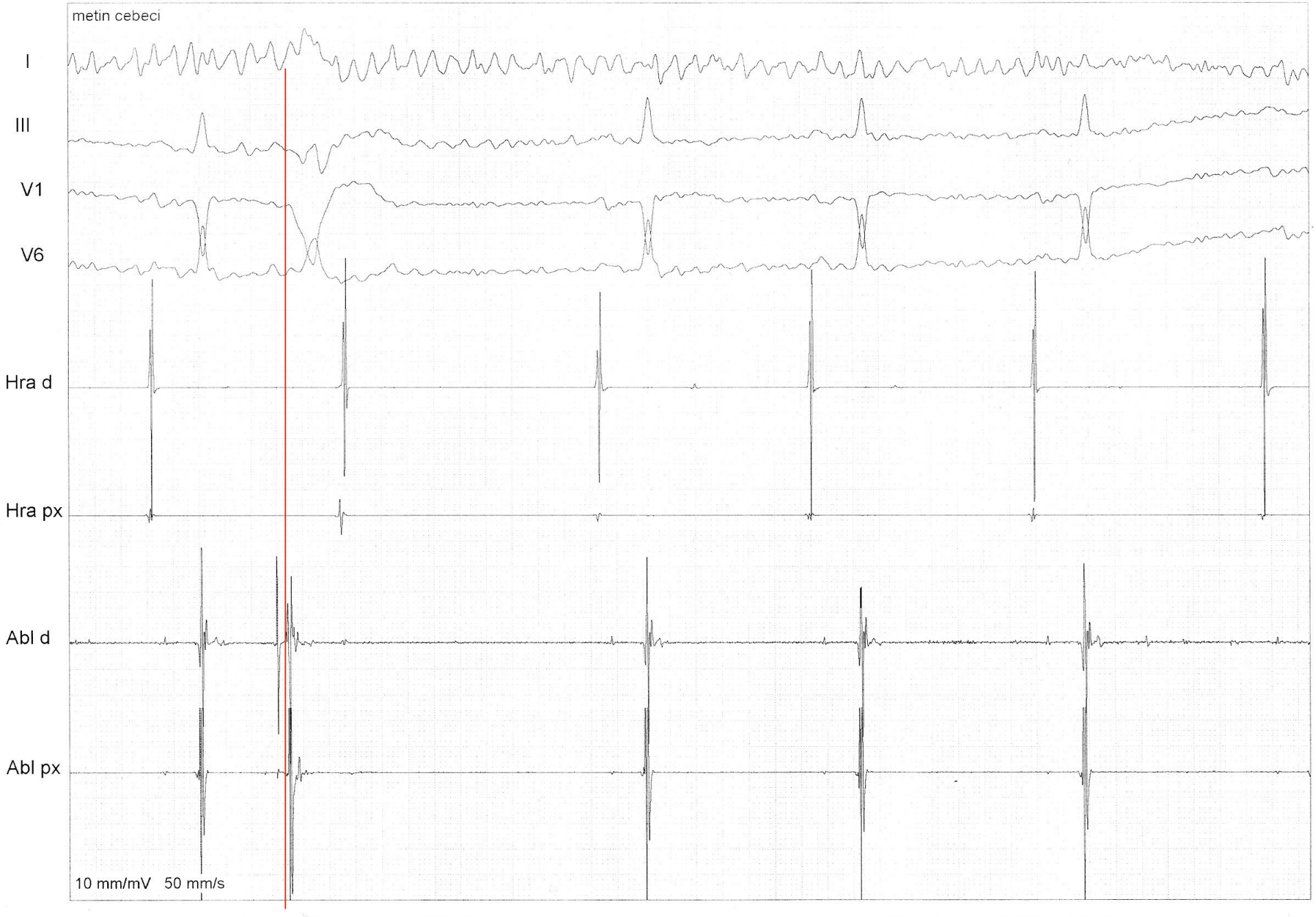

Patient : cebeci metin / vt / 1984 File : C:\PAT\metin cebeci\RF.000

Offline printed on : 13-01-2011 at 17:26:29.

metin cebeci
I
II
III
AVR
AVL
AVF
V1
V2
V3
V4
V5
V6
10 mm/mV 25 mm/s

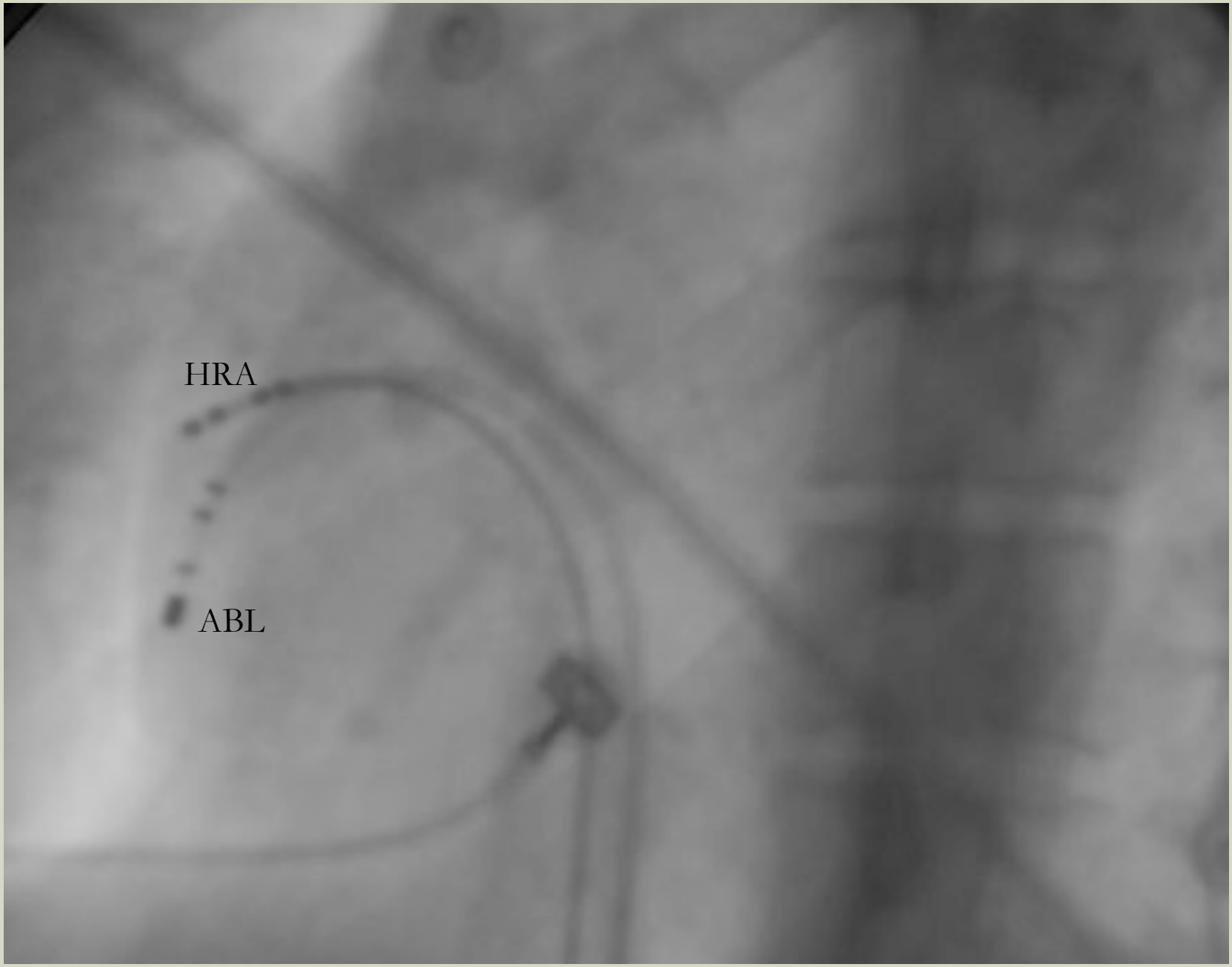

LAO

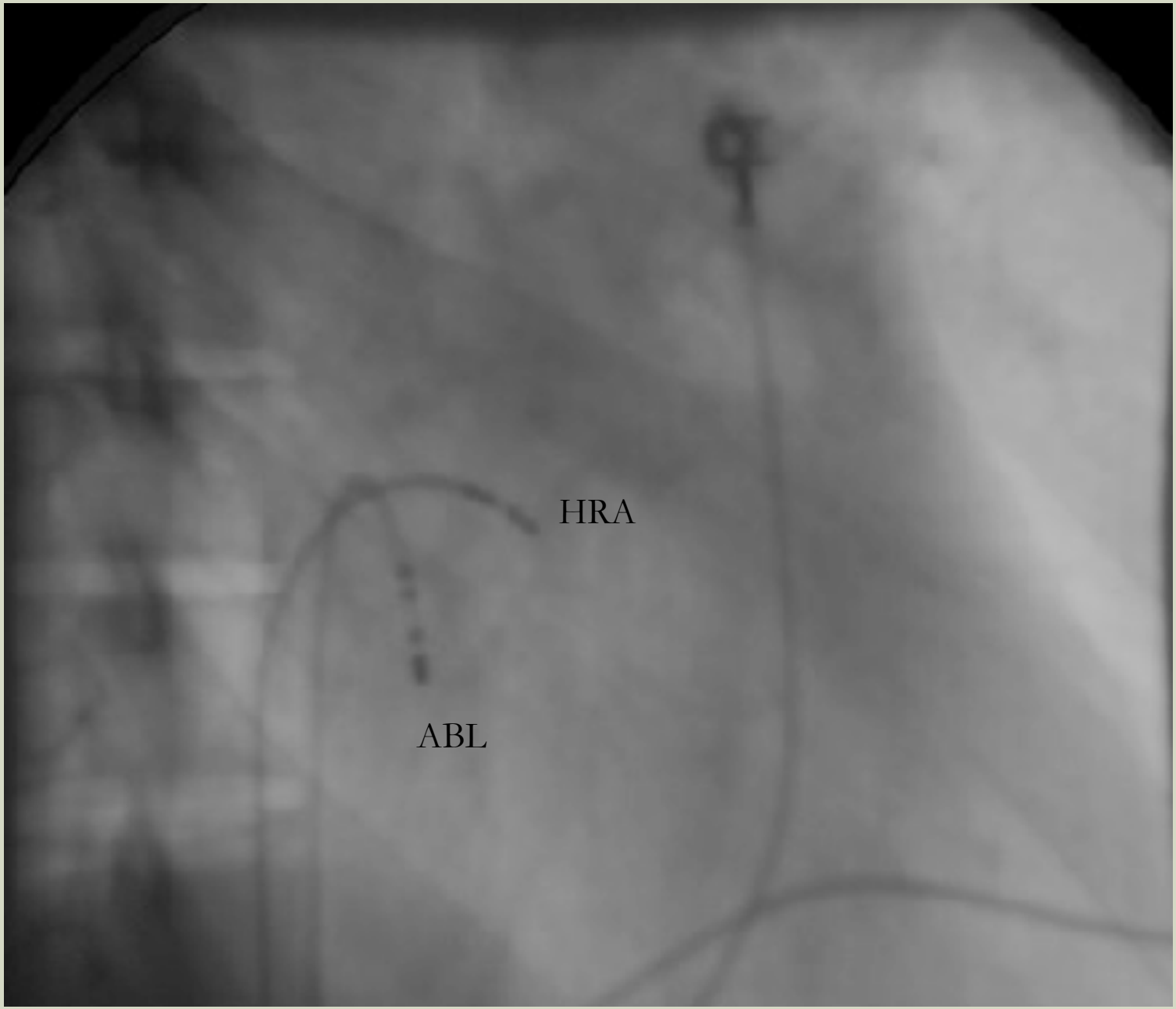

RAO

Case 7

- 36 years old male
- Frequent PVC for 5 years
- Echo: LVEF:% 35- 40
- ECG:Frequent PVC
- HOLTER:20000 PVC/24 hour
- KAG :Normal

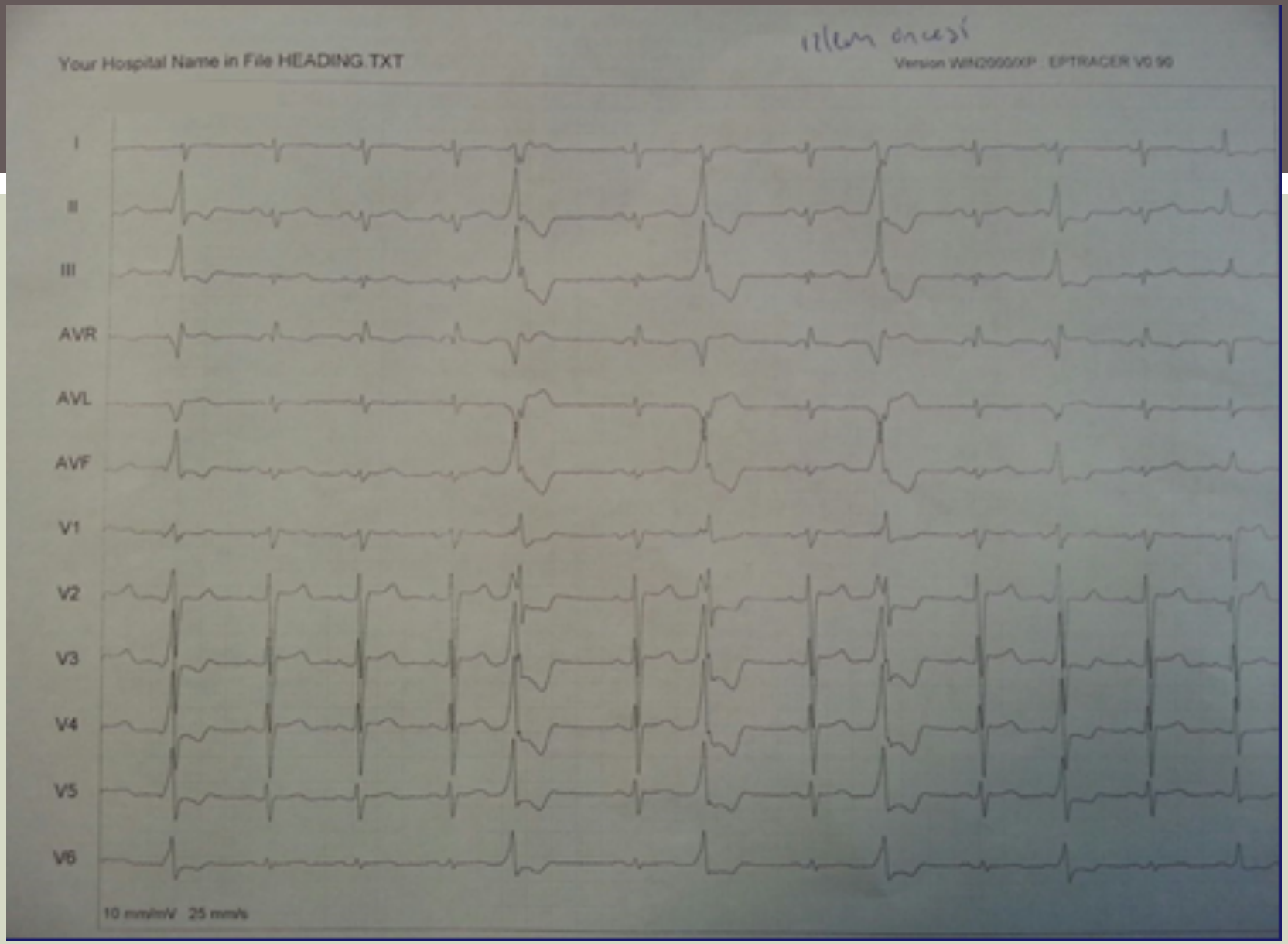
Your Hospital Name in File HEADING.TXT
Version WIN2000/XP EPTRACER V0.90
I
II
III
AVR
AVL
AVF
V1
V2
V3
V4
V5
V6
10 mm/mV 25 mm/s

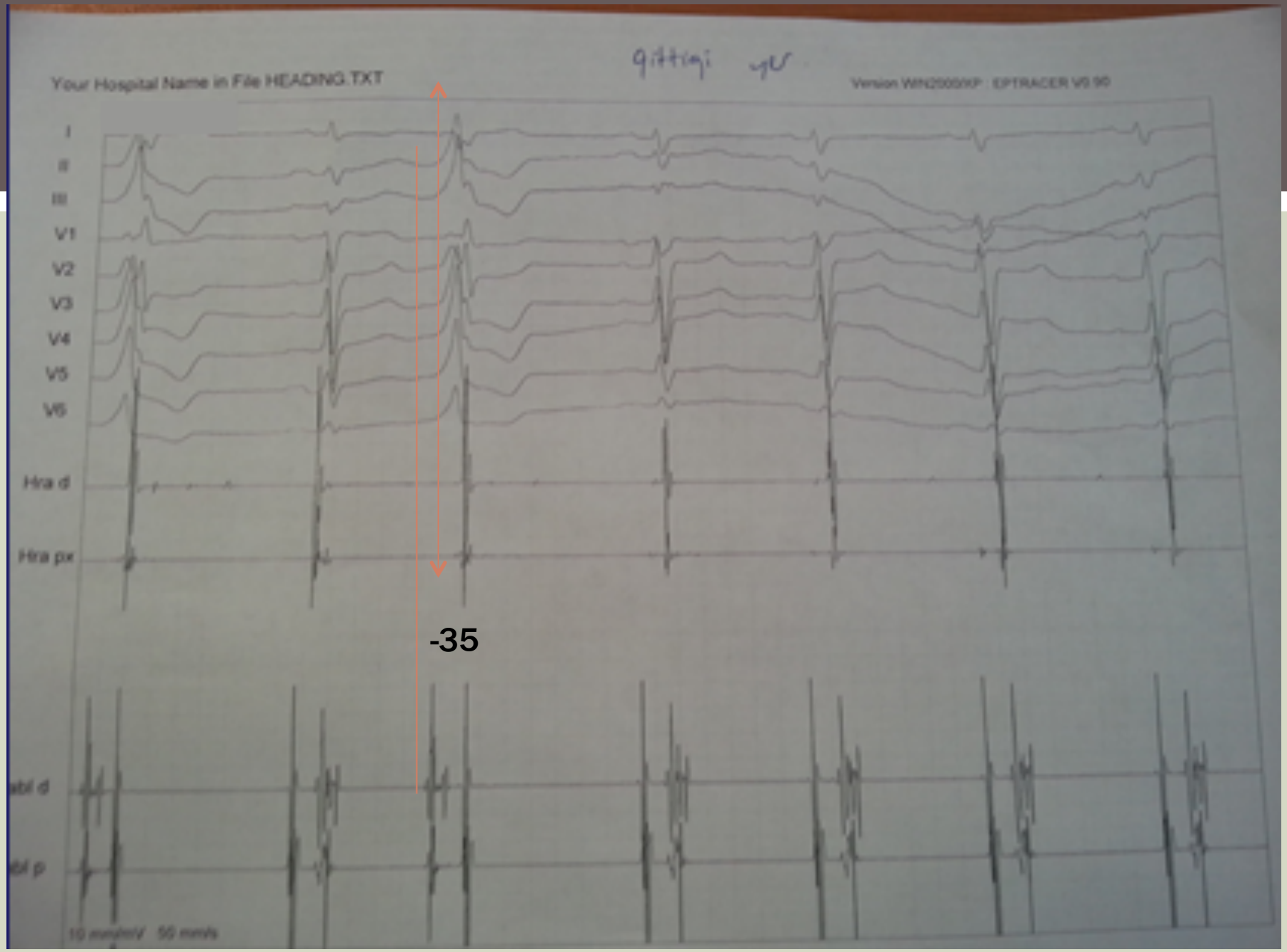
Your Hospital Name in File HEADING.TXT
I
II
III
V1
V2
V3
V4
V5
V6
Hra d
Hra px
-35
10 mm/mV 50 mm/s

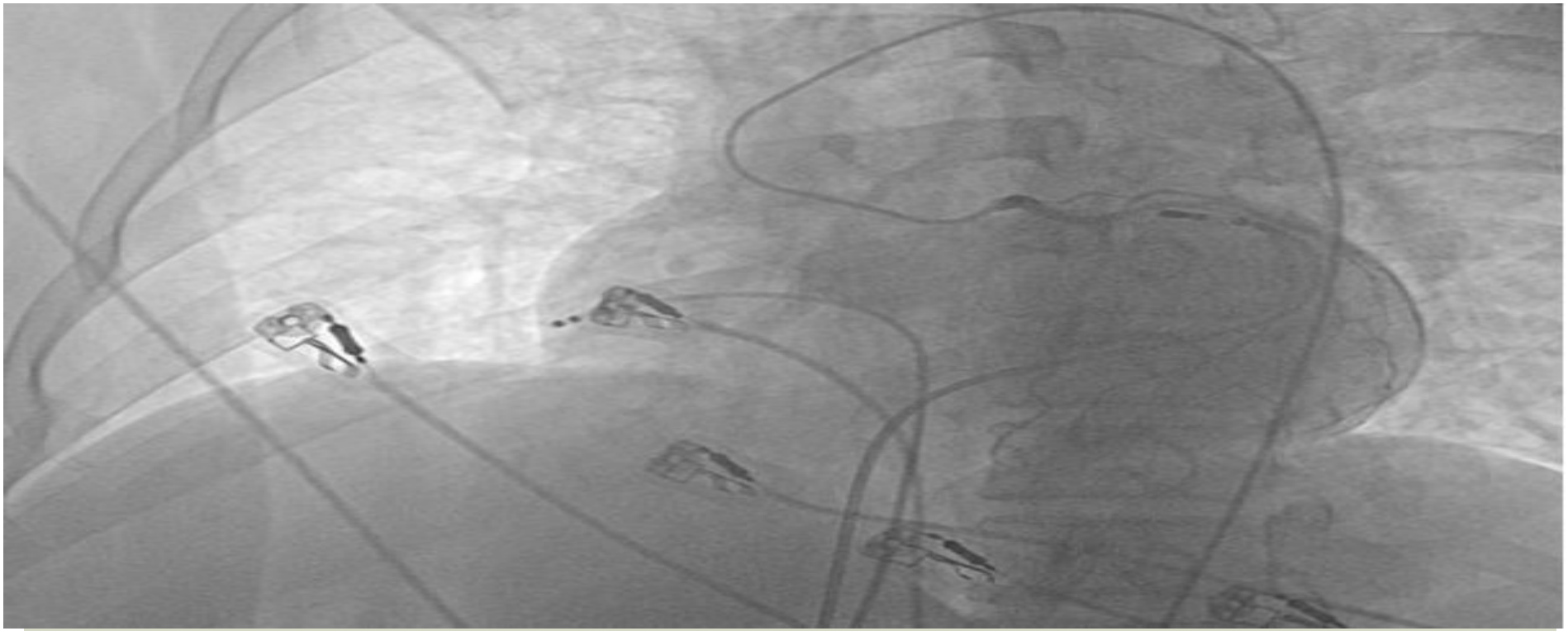

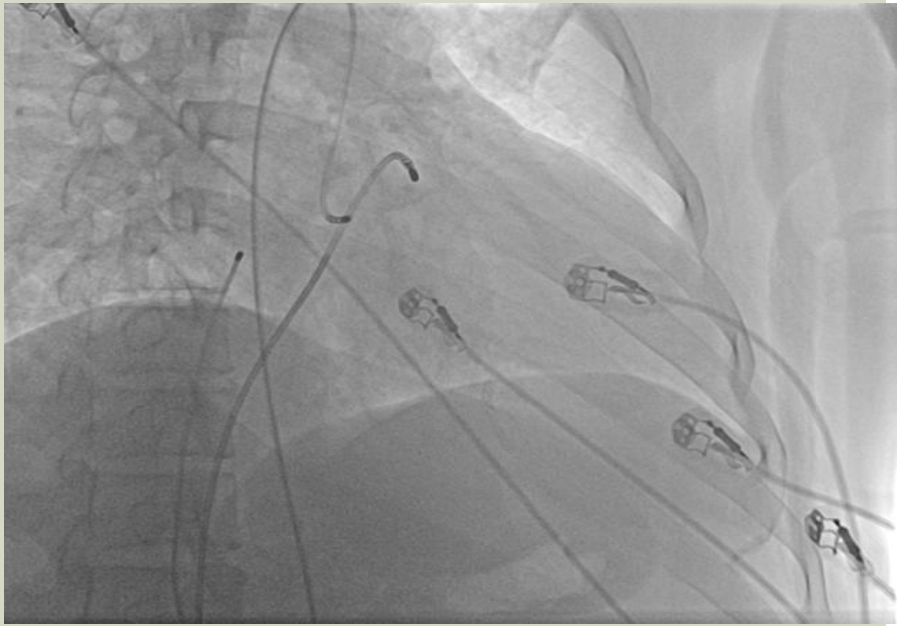

Case 8

- 39 years old male
- Frequent PVC for 2 years
- NO structural heart disease
- ECG:Frequent PVC
- 2 previous failed ablation
- HOLTER:12300 PVC/24 hour

EP Tracer

Version WIN2000/XP : EPTRACER V0.77

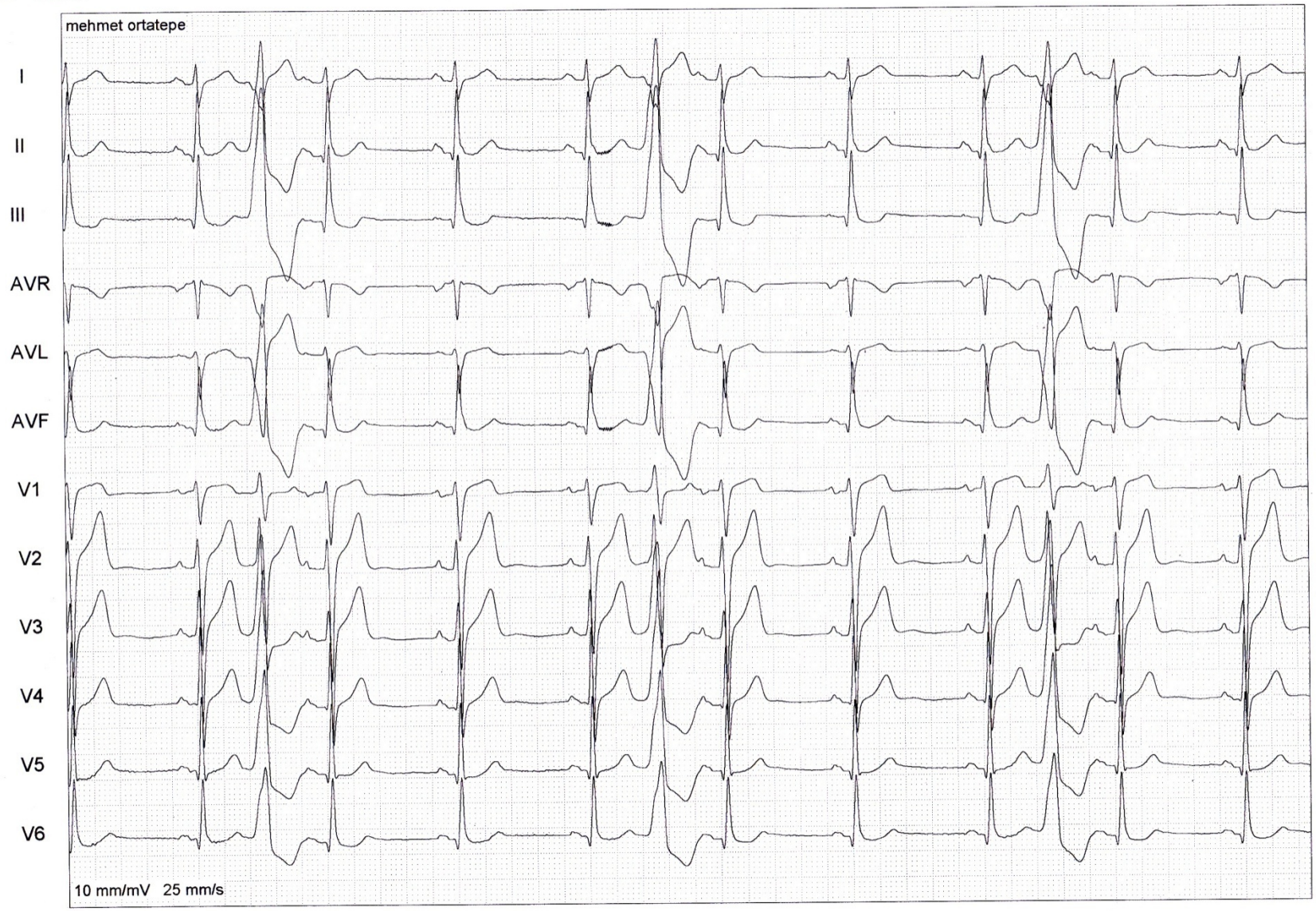

Patient : ortatepe mehmet / ves rf / 1973 File : C:\PAT\mehmet ortatepe\RF.000
Comment : giris

Offline printed on : 21-09-2012 at 20:37:51.
File recorded on : 17.05.2012 at 20:34:42. Time in file 0 msec.

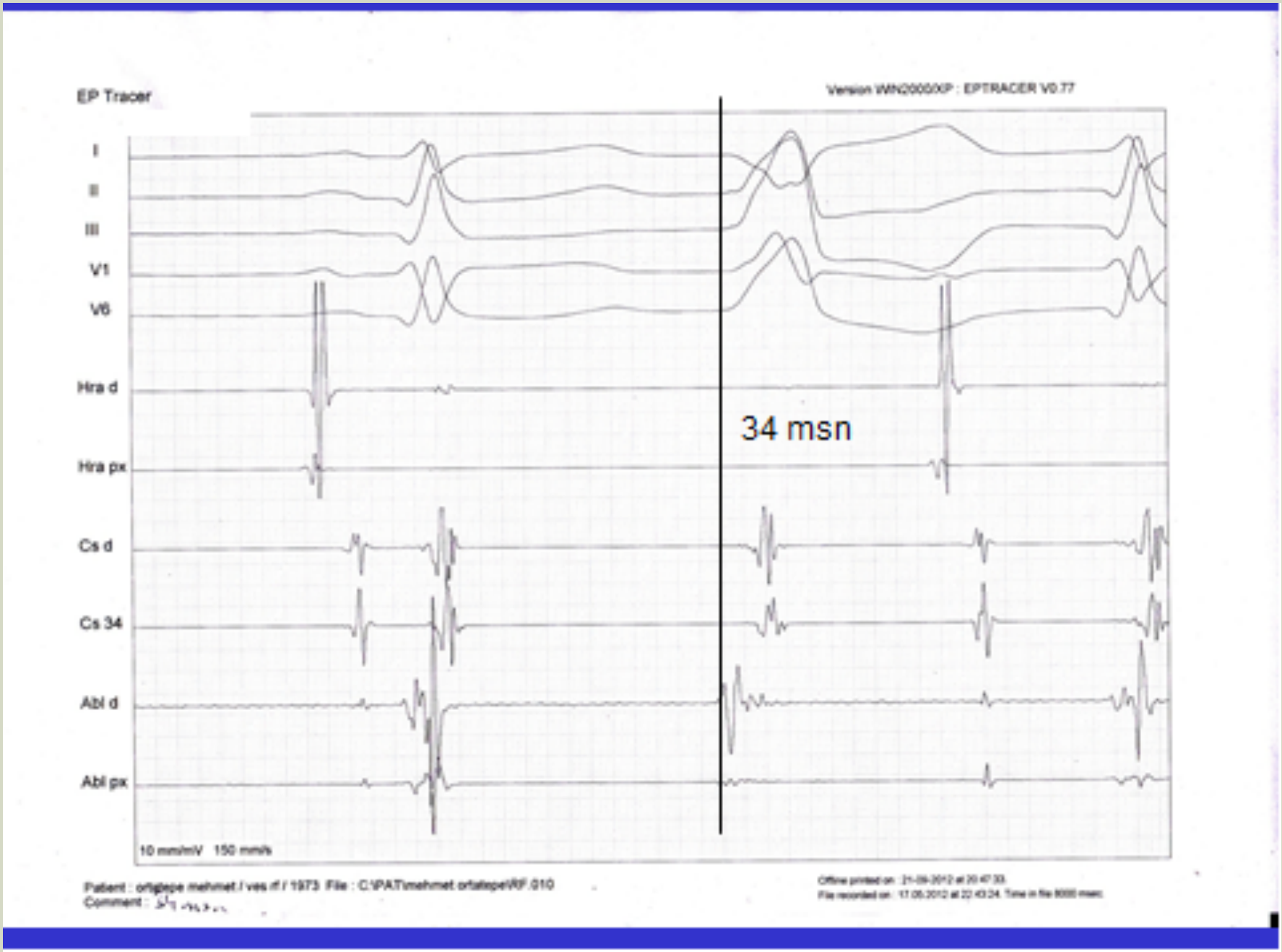
EP Tracer
Version WIN2000/XP : EPTRACER V0.77
I
II
III
V1
V6
Hra d
Hra px
Cs d
Cs 34
Abl d
Abl px
34 msn
10 mm/mV 150 mm/s
Patient : ortatepe mehmet / ves rf / 1973 File : C:\PAT\mehmet ortatepe\RF.010
Comment :

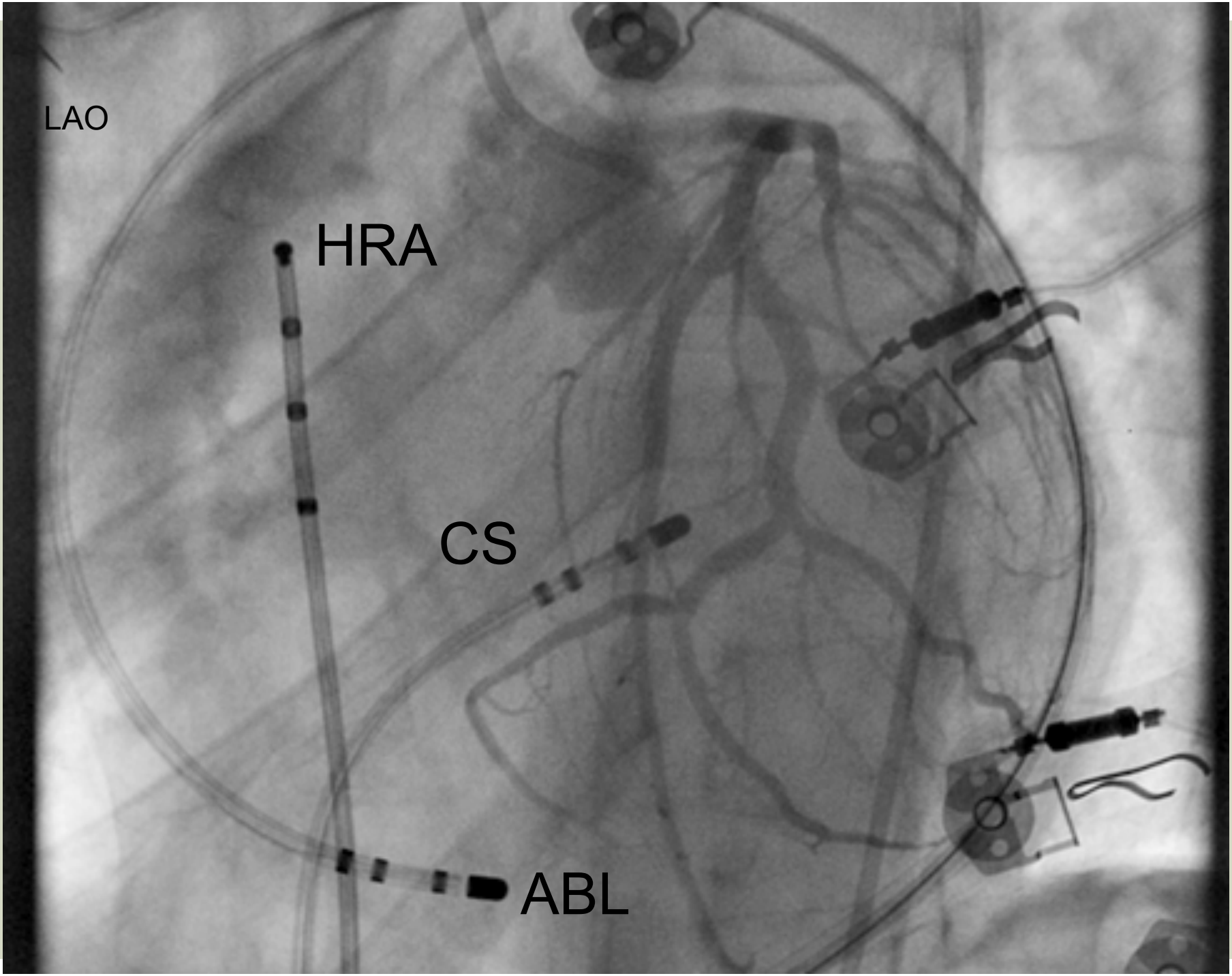
LAO
HRA
CS
ABL

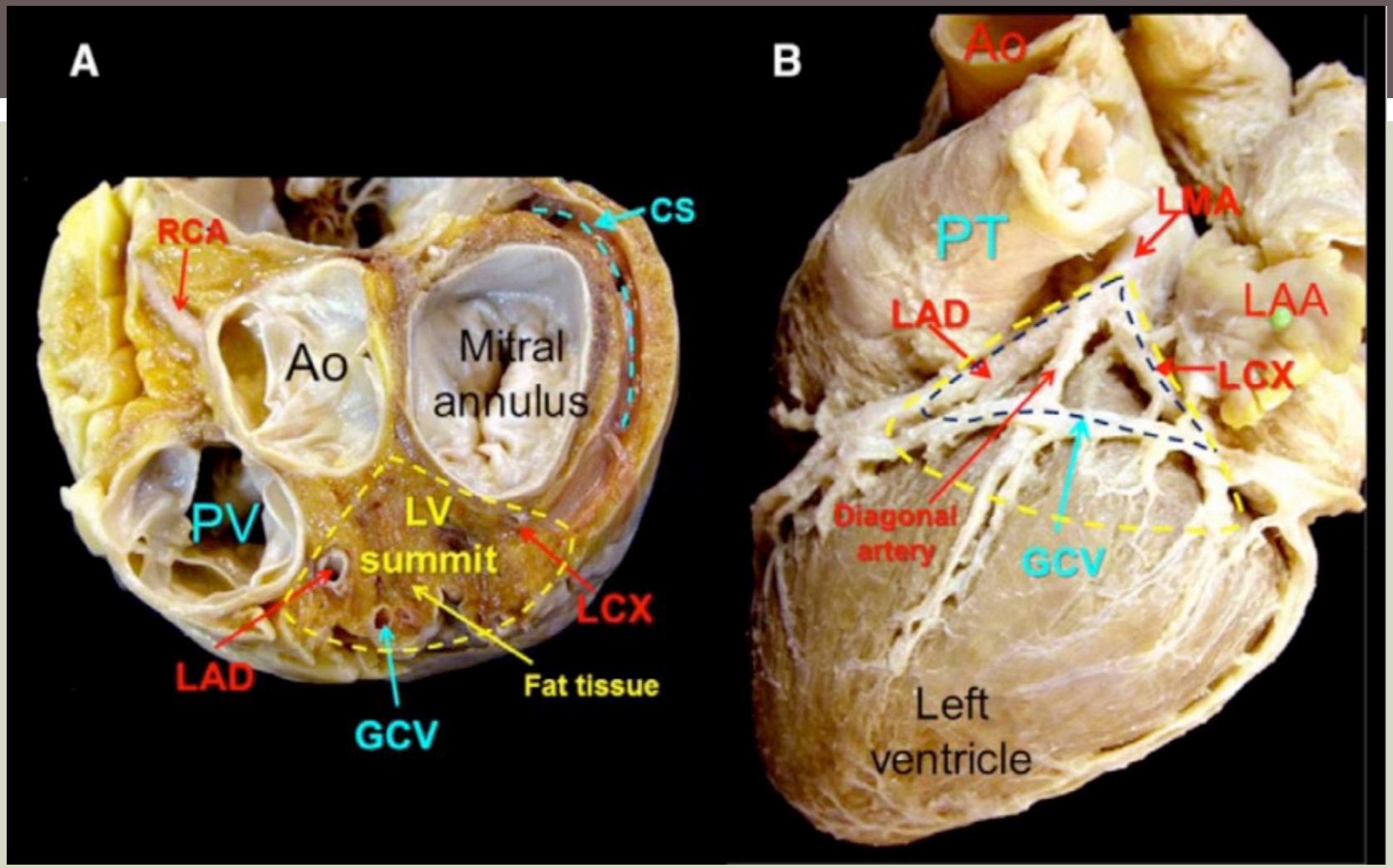
A
RCA
CS
Ao
Mitral
annulus
PV
LV
summit
LCX
LAD
Fat tissue
GCV
B
Ao
PT
LMA
LAA
LAD
LCX
Diagonal
artery
GCV
Left
ventricle