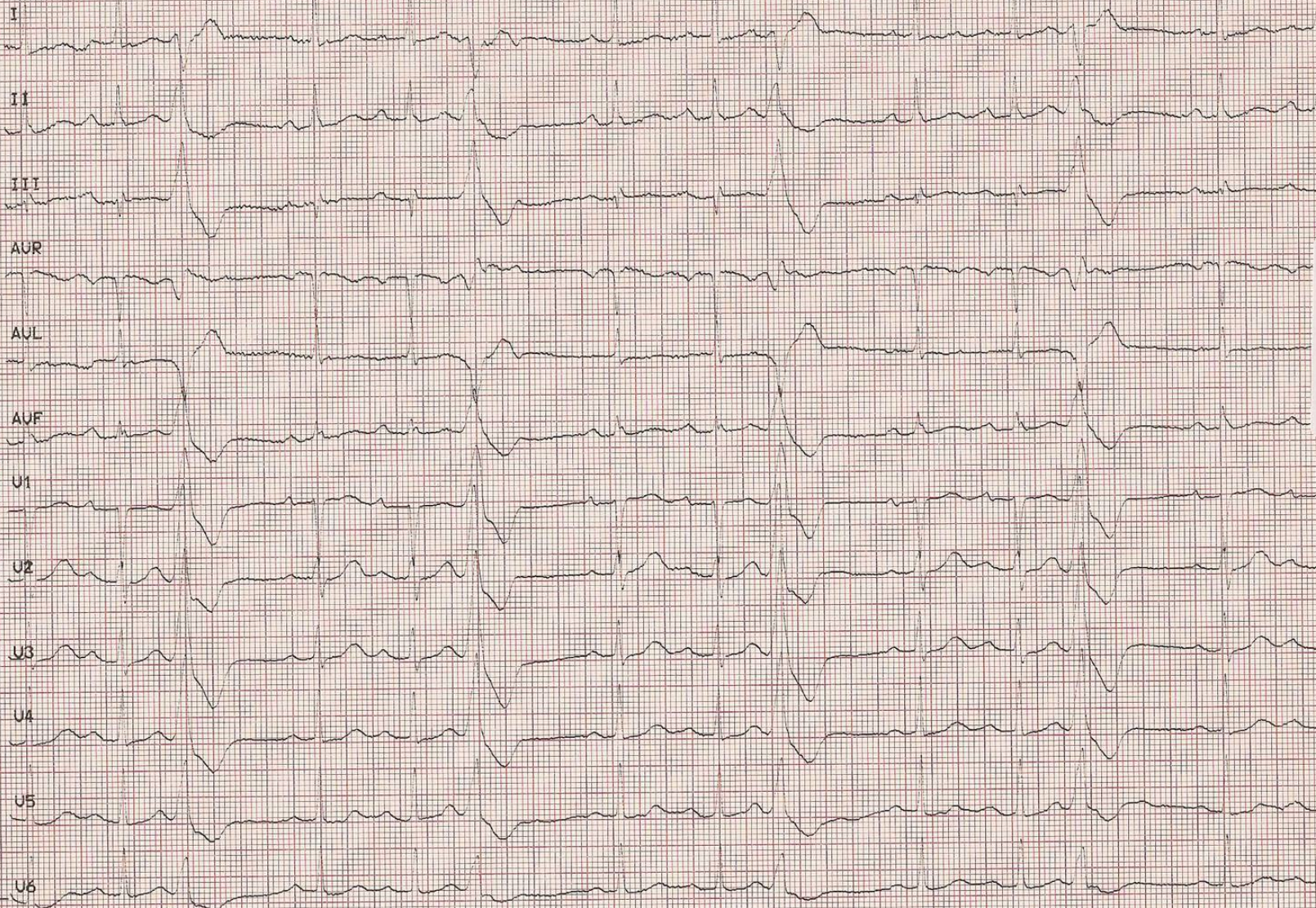


Tips and Tricks for VT ablation: Lessons from Adult Cases I:ECG INTERPRETATION

Sedat KÖSE, MD
Department of Cardiology
Liv Hospital
Ankara, TURKEY

CASE 1

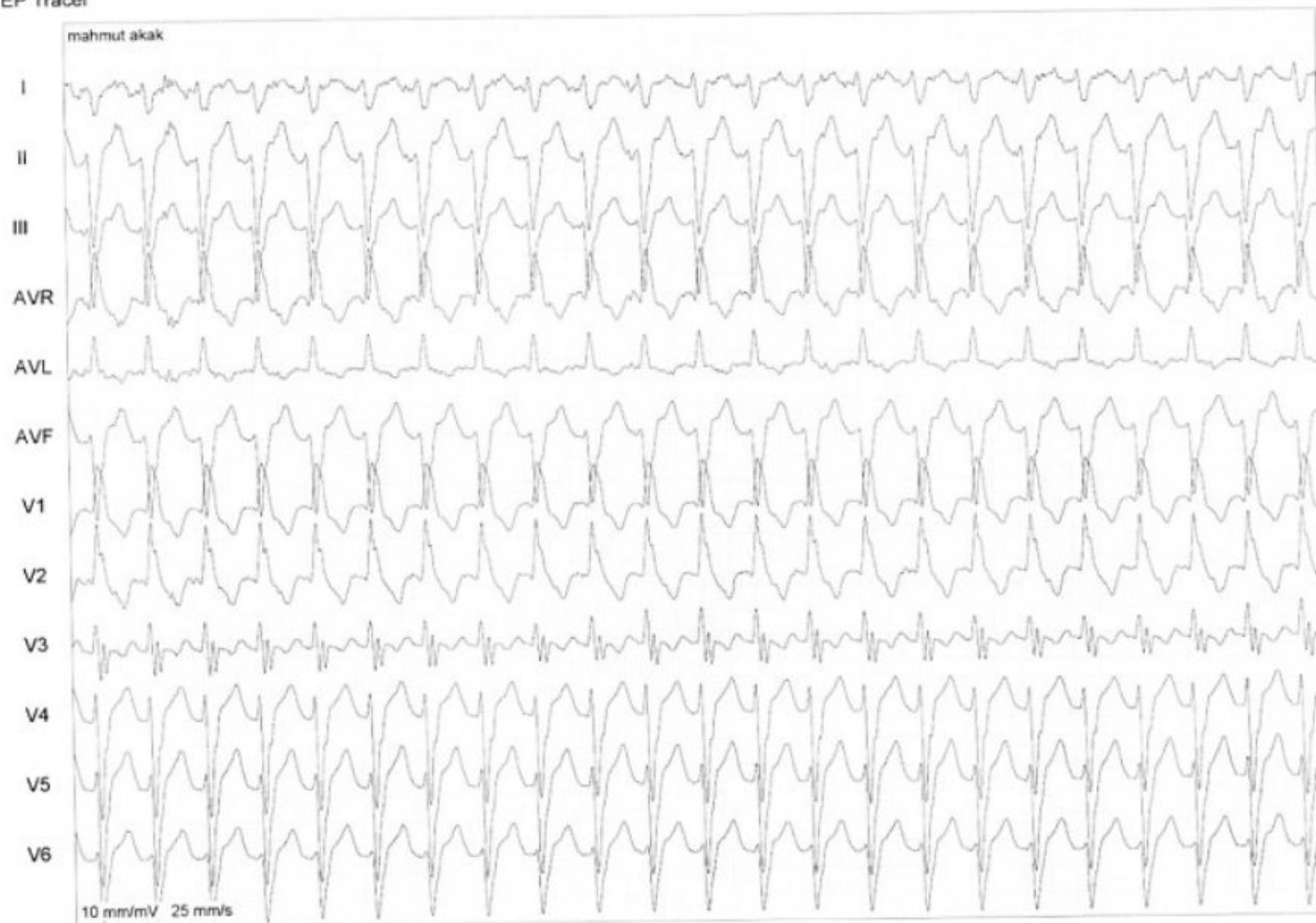- 51 year old female
- Frequent ventricular ectopy and non-sustained VT episodes
- Resistant to metoprolol, verapamil, sotalol, propafenone
- Normal coronary artery anatomy, LVEF:64%



REMZİVE MADEN
10067534
G.T 05.03.2010
Birim: KARDİYOLOJİ
Cinsiyet: KADIN Yaş: 51
Doğum Tarihi: 01.01.1959
TC Kimlik: 38176851638

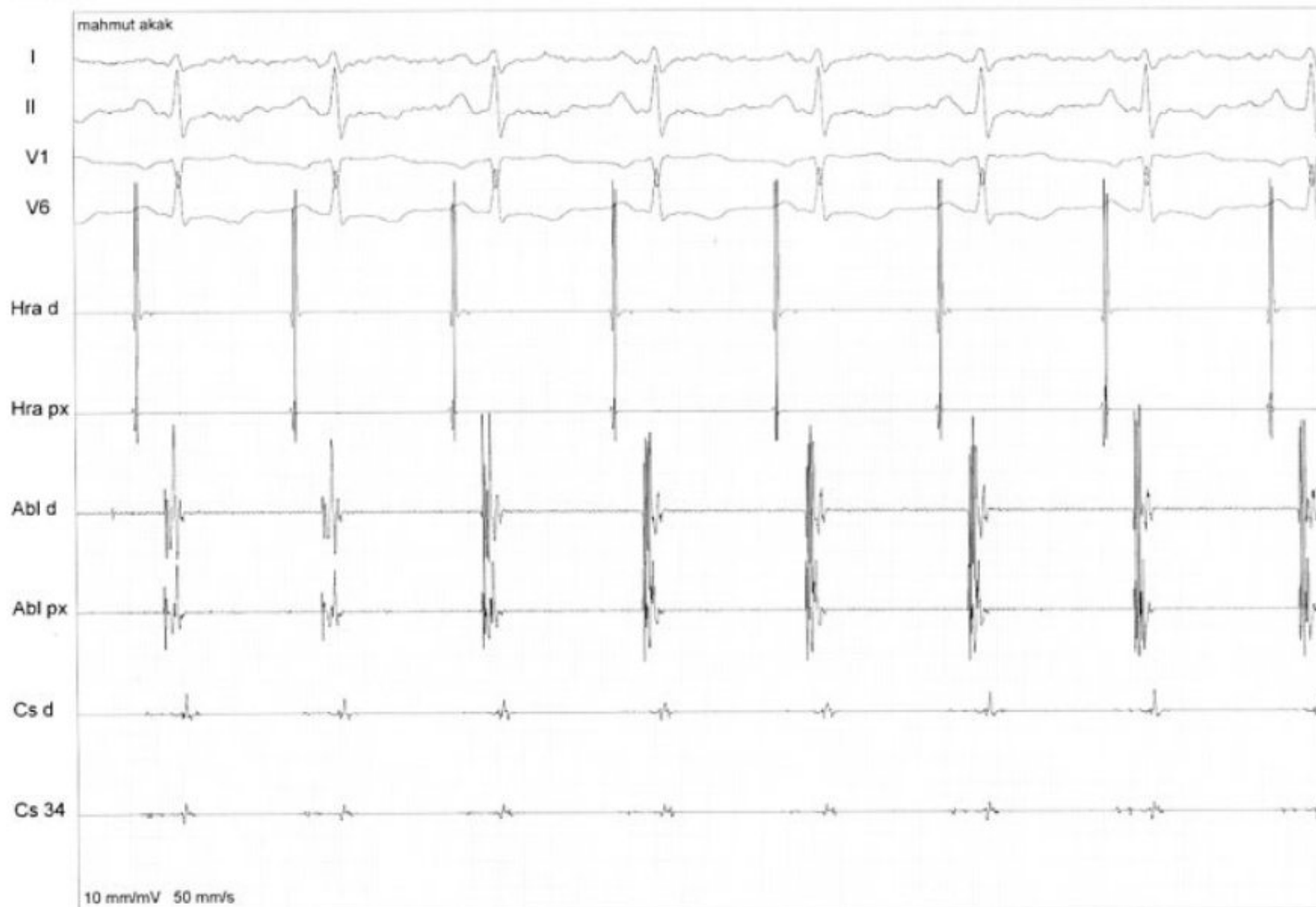CASE 2

- 30 year old male
- Complaint of palpitation
- Wide QRS complex tachycardia episodes (RBBB/superior axis) resistant to antiarrhythmic drugs
- No organic heart disease



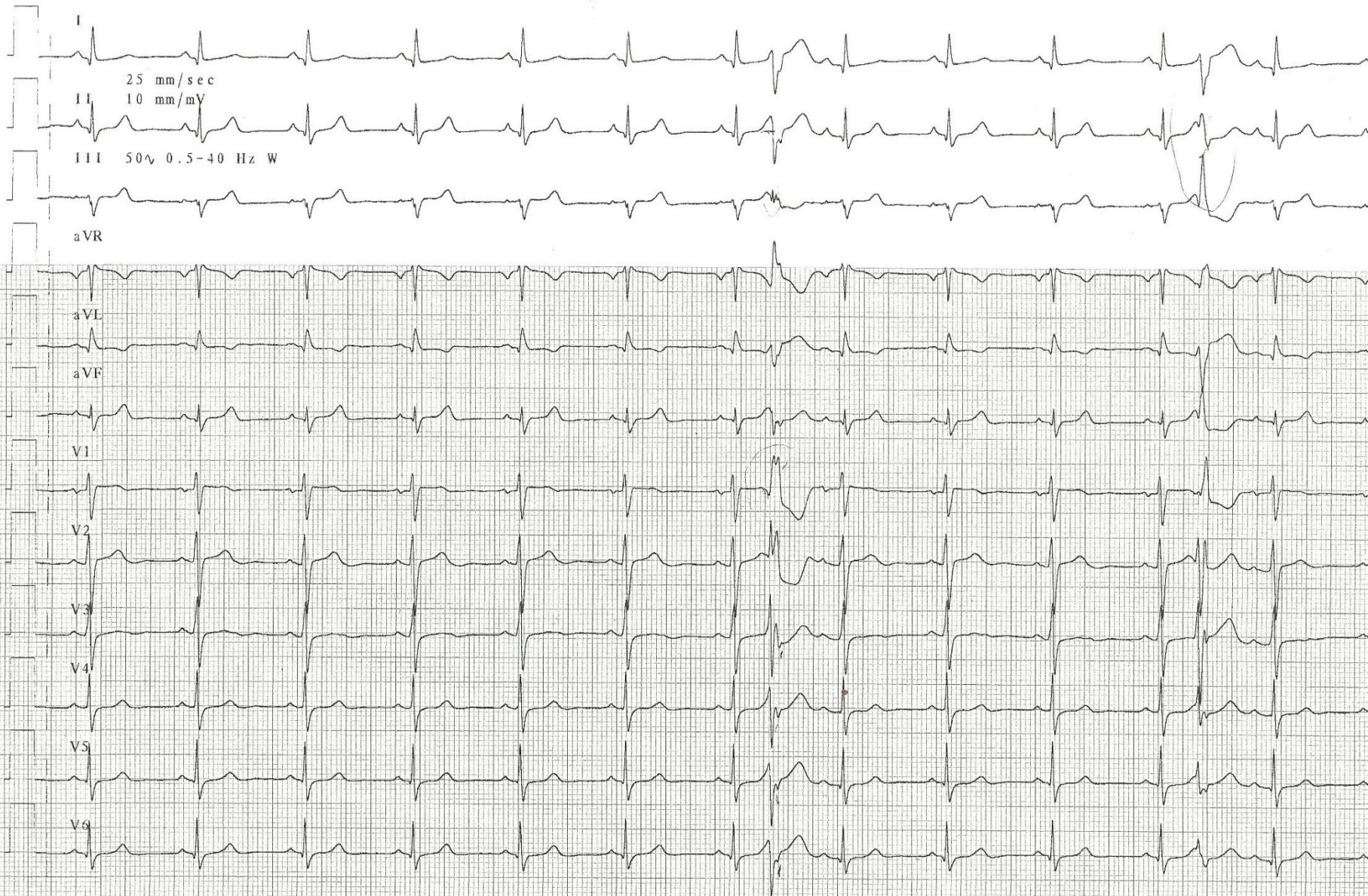
EP Tracer

Version WIN2000/XP : EPTRACER V0.77



CASE 3

- 48 year old female
- Complaint of presyncope and palpitation for 5 years
- Normal neurological exam
- 24 h Holter ECG: rare (278 beats/24 h) premature ventricular contractions
- No organic heart disease

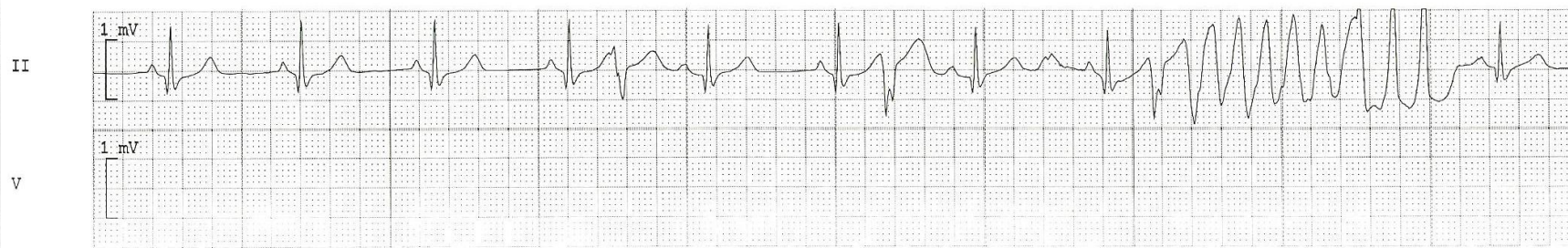


LOC 10000-1000

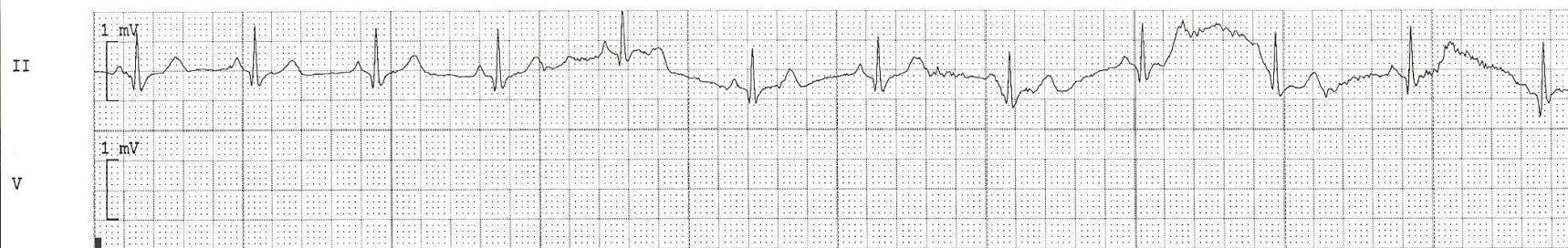01767

H.P.I

ID#	HR.....	VF bpm
Hospital GATA	ARR.....	VF
Monitoring Unit MON-02	NBP S....	132 mmHg
Care Unit KYB-OZ	NBP D....	77 mmHg
Bed KYB-OZ1	NBP M....	103 mmHg



14:24:39

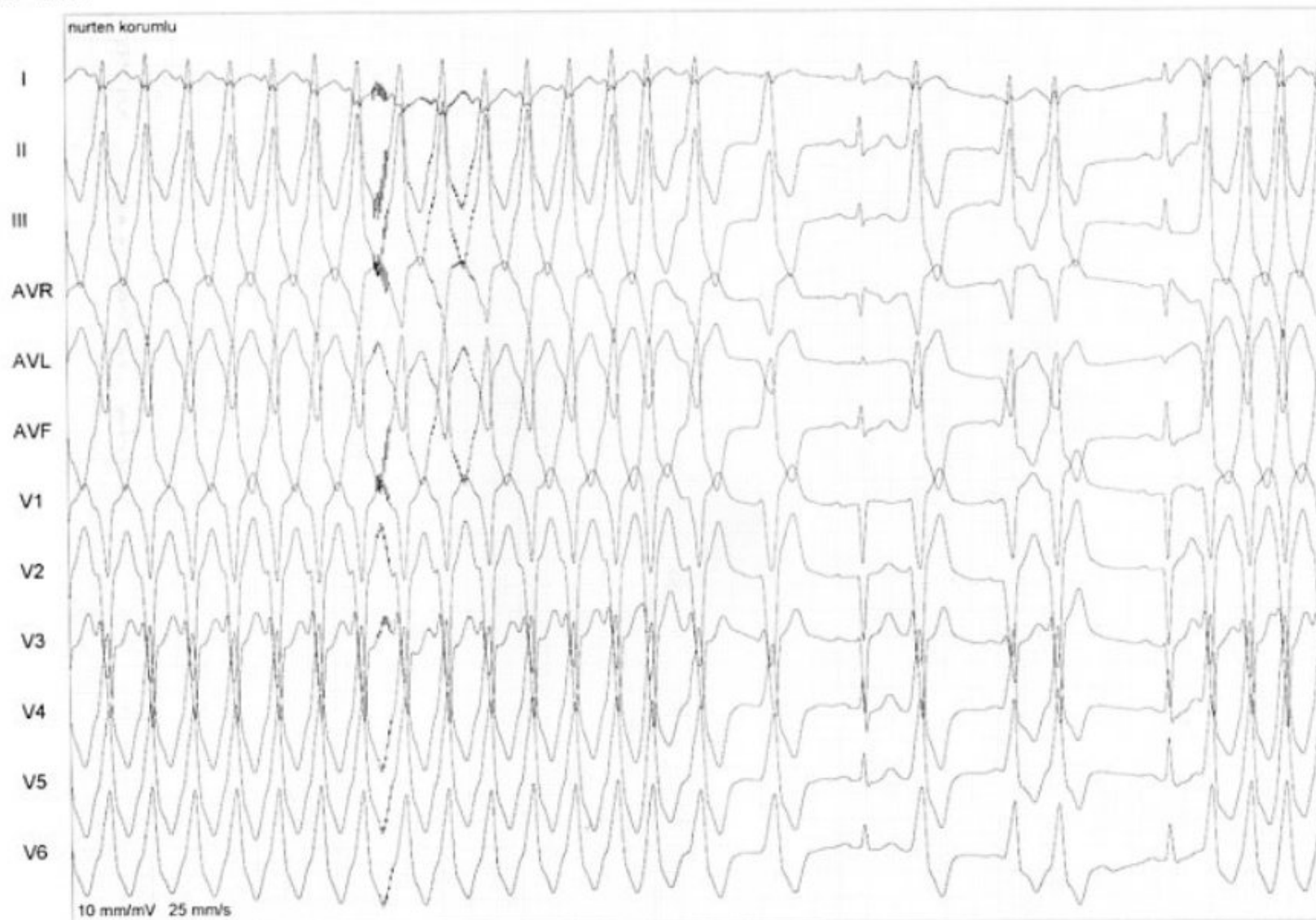


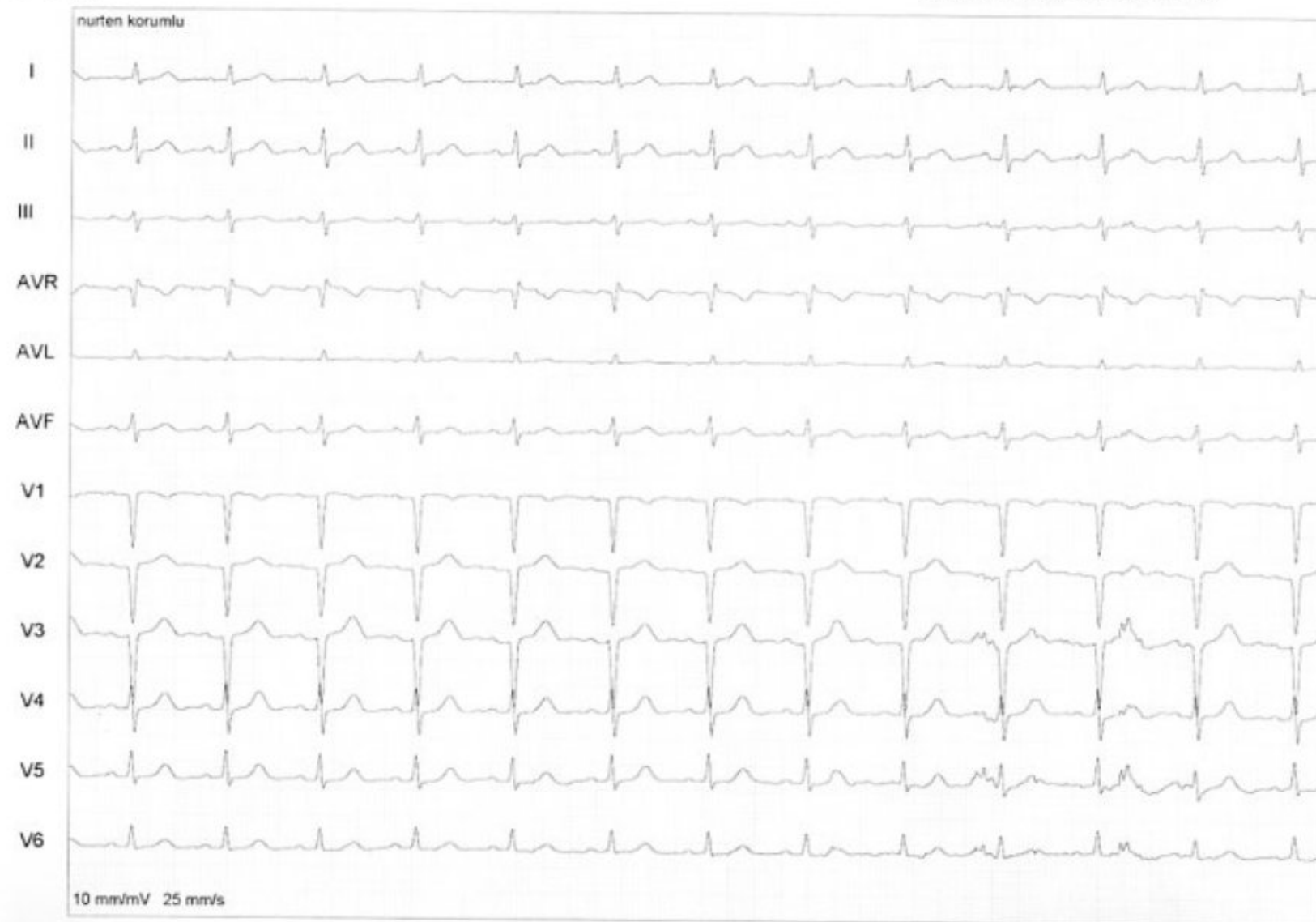14:24:49

ARR: VF! 17-Oct-2011 14:24:49

CASE 4

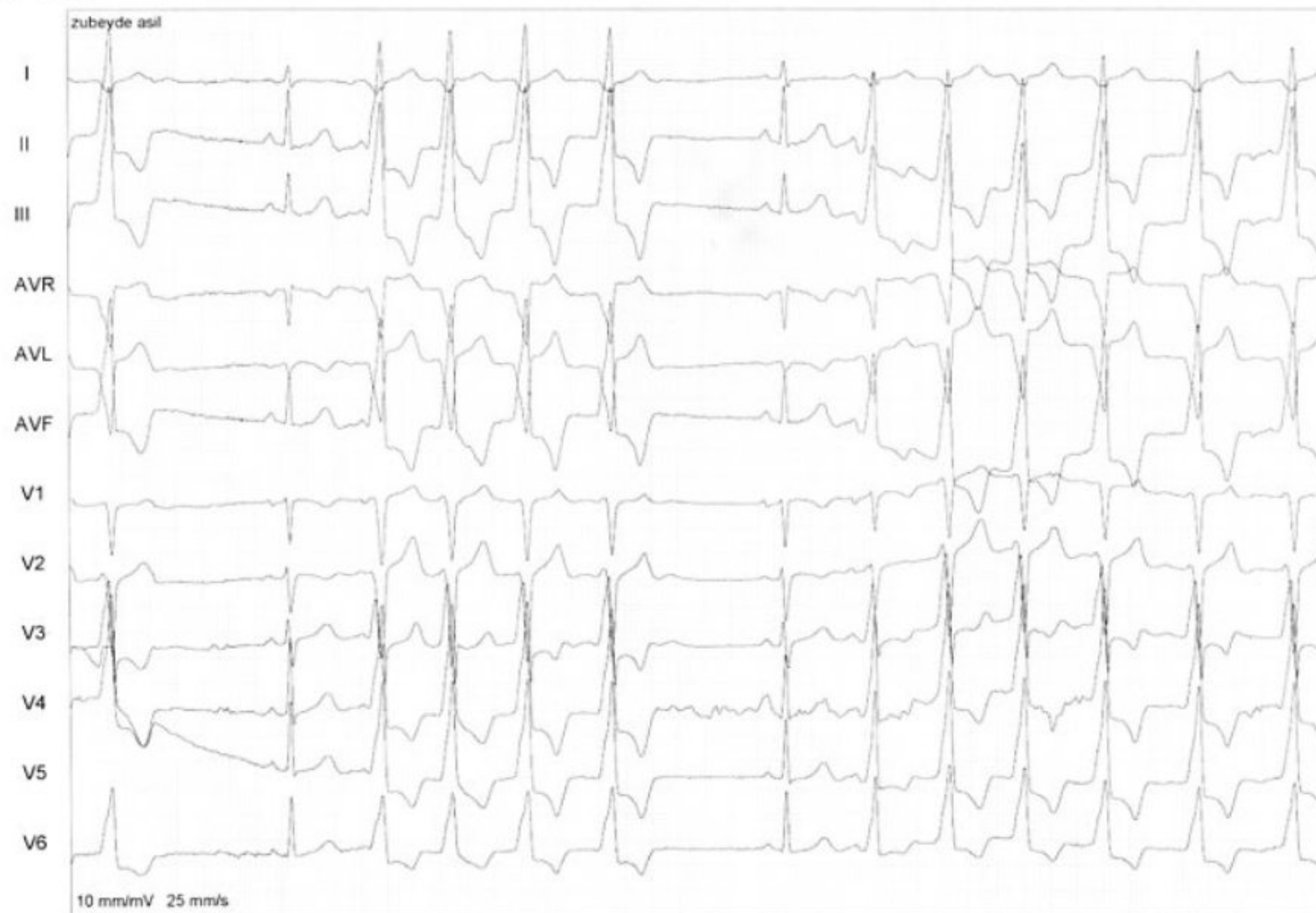
- 49 year old female
- Palpitation and pre-syncope
- Monomorphic VT episodes resistant to antiarrhythmic drugs
- No organic heart diseases

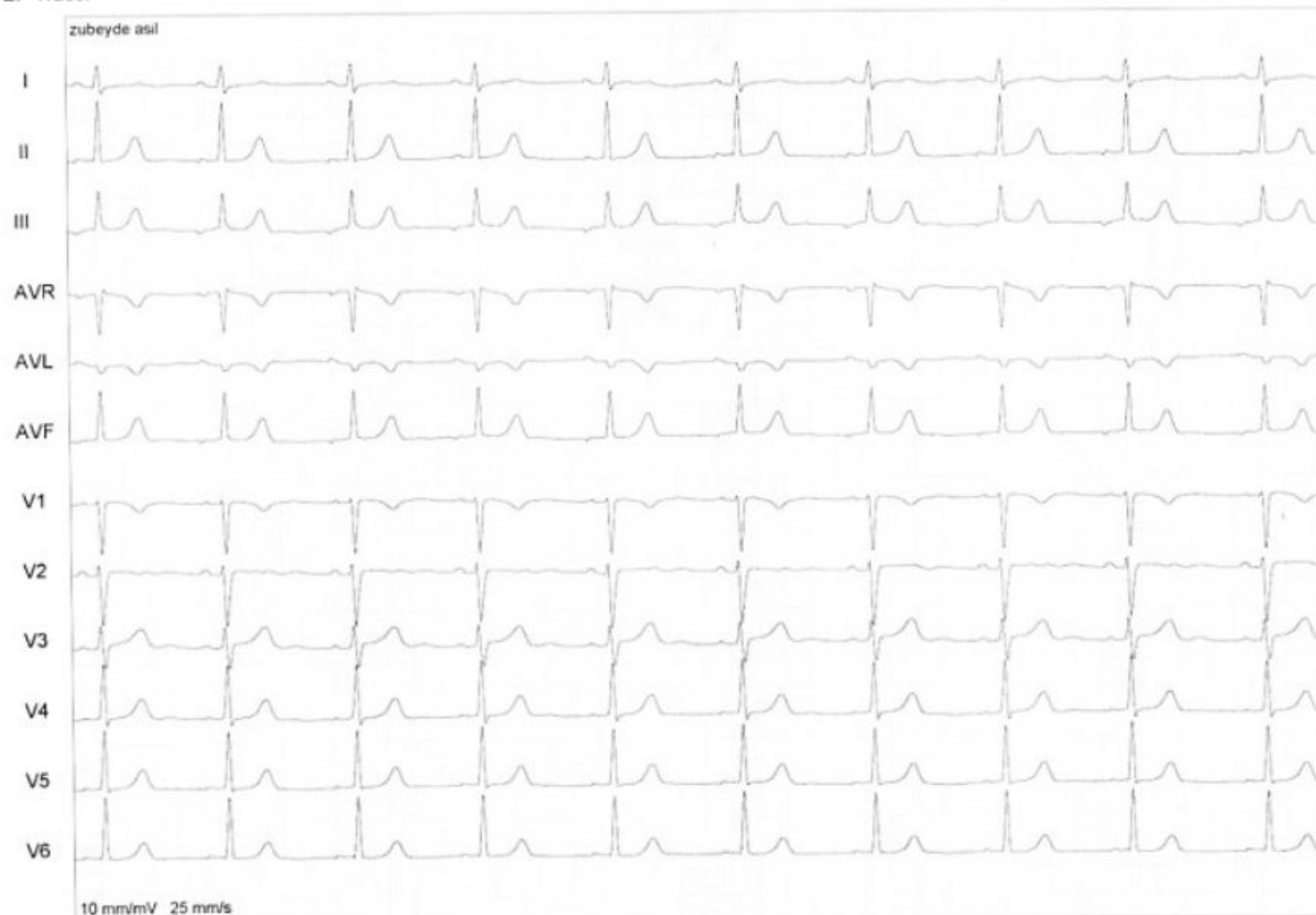




CASE 5

- 26 year old female
- Complaint of palpitation
- Non-sustained VT episodes resistant to antiarrhythmics
- Failed ablation history
- No organic heart disease





CASE 6

- 61 year old male
- Complaint of palpitation for almost 30 years
- Frequent episodes of PVC resistant to antiarrhythmics; 25000 pvc/24 hour
- 2 Failed ablation attempts
- LV EF:% 40, moderate mitral regurgitation
- Stable CAD ,previous 2 coronary stent implantation 1 year ago
- No prior MI



